



Variations in human renal arteries

Tania Regina Santos Soares^{1*}, Juliana Soares Ferraz², Camila Buziquia Dartibale³ and Inandira Rafaella Marco Oliveira²

¹Departamento de Ciências Morfológicas, Universidade Estadual de Maringá, Av. Colombo, 5790, 87020-900, Maringá, Paraná, Brazil. ²Curso de Graduação em Medicina, Faculdade Ingá, Maringá, Paraná, Brazil. ³Curso de Graduação em Medicina, Universidade Estadual de Maringá, Maringá, Paraná, Brazil. *Author for correspondence. E-mail: trdssoares@uem.br.

ABSTRACT. Kidneys are especially irrigated by a pair of arteries originated from the aorta artery. The presence of additional renal arteries is the most frequent variation in this vascularization, an aspect important to be known in renal surgeries and radiological procedures (SAMPAIO; PASSOS, 1992). This study aimed to observe the prevalence of numeric variation and the origin of the additional renal artery. For this purpose, 24 cadavers and 26 blocks were used; each block contained the kidneys and their respective arteries and veins, the abdominal aorta and inferior vena cava, taken from adults of different ethnicity and genders, from the Department of Morphological Science, State University of Maringá (DCM/UEM) and Laboratory of Anatomy, Ingá Faculty (UNINGÁ). Among the examined pieces, 45 (forty five) presented single renal arteries and 5 (five) had double renal arteries; 3 (three) had only additional renal artery on the right side, and 1 (one) showed additional renal artery on the left side, and only 1 (one) also showed bilateral additional renal arteries.

Keywords: additional, multiple, anatomy, vascularization, kidney, vessels.

Variações nas artérias renais humanas

RESUMO. Os rins são irrigados, principalmente, por um par de artérias originadas da artéria aorta. A presença de artérias renais adicionais corresponde à variação mais frequente dessa vascularização, sendo ela importante em cirurgias renais e procedimentos radiológicos (SAMPAIO; PASSOS, 1992). Esta pesquisa tem por objetivo observar a prevalência de variação numérica existente e a lateralidade de origem das aa. renais adicionais. Foram utilizados 24 cadáveres dissecados e 26 blocos contendo rins, suas respectivas artérias e veias renais, parte abdominal da aorta e v. cava inferior, retirados de indivíduos adultos de diferentes etnias e sexo, provenientes do Departamento de Ciências Morfológicas da Universidade Estadual de Maringá (DCM/UEM) e Laboratório de Anatomia da Faculdade Ingá (UNINGÁ). Do total de peças analisadas, 45 apresentam apenas aa. renais únicas, cinco apresentam aa. renais duplas. Dessas, três apresentam apenas a. renal adicional direita, uma apresenta apenas a. renal adicional esquerda e uma apresenta aa. renais adicionais bilateralmente.

Palavras-chave: adicionais, múltiplas, anatomia, vascularização, rim, vasos.

Introduction

Kidney arteries represent the 5th branch of the abdominal aorta, and arise from the lateral part of this artery, between the upper edge of the L1 and the lower edge of L2.

In the descriptions of Özkan et al. (2006), the main renal artery, direct branch of the aorta, arises from the upper edge of L1 and lower edge of L2 in 98% of patients, and in 74% the origin of the extra renal arteries is located in the same region. The regular origin of the renal artery is at the level of L1-L2 intervertebral discs.

Kadir (1991) observed that in 75% of the general population, the main renal artery originates at level of the intervertebral disc of L1 and L2, and in 25%,

between T12 and L2. In the study performed by Özkan et al. (2006), 23% of the right renal arteries and 22% of the left renal arteries emerge between the intervertebral disc of L1 and L2, different from the author cited above.

Usually each kidney receives one bilateral renal artery with about 6-8mm diameter, but this measure varies according to kidney volume. Due to differences in their courses, the characteristics of the right and left renal arteries are described separately as follow.

The right renal artery has from 3 to 5 cm length, and 5 to 7 mm diameter. It arises from the right side of abdominal aorta, inferior-laterally to the origin of the superior mesenteric artery. It is located anteriorly to the spine and runs almost transversely

to the side, crossing anteriorly the pillars of the diaphragm and the muscles psoas major and minor; being also situated anteriorly to the lumbar sympathetic chain and the ascending lumbar vein; and posteriorly to the head of the pancreas, descending part of duodenum, inferior vena cava and right renal vein. However, in more than one third of cases, it is possible to find the right renal artery anteriorly and crisscrossed with the right renal vein (TESTUT; LATARJET, 1978).

The left renal artery is as voluminous as the right, and originates superiorly to the origin of the right renal artery. In general the length of this blood vessel does not exceed 3 cm, and is at least one centimeter shorter than the right. As well as the right artery, the left is located anteriorly to the spine and psoas major muscle, and posteriorly to the pancreas (TESTUT; LATARJET, 1978).

Along its course, the renal artery reaches the upper end of renal hilum, just before it divides into 2, 3, 4 terminal branches that reach the kidney anteriorly to renal pelvis (TESTUT; JACOB, 1977).

Although the literature describes that generally there is a renal artery for each respective kidney, we may find variations of origin and number (OLAVE et al., 2007). Putz and Pabst (2006) quoted the following variations in the renal arterial network and their approximate incidences: presence of an upper pole artery as a branch of the renal artery (13%); origin of two renal arteries from the aorta to the renal hilum (10%); presence of an accessory upper pole artery (7%); existence of an accessory lower pole artery (5%). Aumüller et al. (2009) cite the following variations in renal arteries: one or two renal arteries from the coeliac trunk; existence of one or two additional arteries (accessory renal arteries) and the course of the artery to a renal pole rather than to the renal hilum.

The renal arteries can also give rise to vessels that usually do not arise from them, as suprarenal arteries, gonadal arteries, pancreatic artery, hepatic artery and some of the colic arteries (WEBER et al., 2009).

The multiple renal arteries can coexist with other variant urovascular structures, like renal vein and multiple ureters. Multiple renal arteries are more frequently observed than multiple renal veins, at ratio 1: 8 (BORDEI et al., 2004).

The knowledge on anatomical variations is essential for renal surgeries and even for radiological procedures (SAMPALIO; PASSOS, 1992). In this way, these variations should be studied to establish new techniques that minimize the additional problems that come with anatomical variations.

The interest in verifying the several renal arteries was aroused due to possible associations between their variations and clinical correlations such as artery diseases and hypertension (VILHOVA et al., 2001).

The presence of multiple renal arteries increases the complexity degree of renal surgeries (BORDEI et al., 2004).

The knowledge of these anatomical variations is also of paramount importance for urologists, radiologists, surgeons in general, when considering a surgical approach, and also for teaching renal vascularization (SALDARRIAGA et al., 2008b; VILHOVA et al., 2001).

This study aimed to observe the prevalence of numeric variation and the origin of the additional renal artery.

Material and methods

In this study, it was used 24 dissected cadavers and 26 blocks containing kidneys, their respective renal arteries and veins, abdominal part of aorta and inferior vena cava, removed from adult individuals of different ethnicities and gender, from the Department of Morphological Sciences, of the State University of Maringá, and Anatomy Laboratory, of the Ingá Faculty (CAAE 0106-10 de 11/05/2010). Twenty-three cadavers were male and 1 female. The anatomical parts studied were fixed in formaldehyde 10%. We observed the frequency of existing numerical variations, and the laterality of origin of the additional renal arteries.

Results

The data obtained was based on a total sample of 24 (48%) cadavers, 95.83% male and 4.17% female, and 26 (52%) blocks, totaling 50 anatomical parts. The variations had consisted of double renal arteries in 5 parts, representing 10% of the total of examined parts and 90% of the parts had no variation in renal arteries (Figure 1).

No variations were found in the cadavers, preventing the correlation between our findings with the gender. All analyzed variations of renal arteries presented double renal arteries.

It was observed among the variations, 6 additional renal arteries, 4 (66.67%) additional right renal arteries and 2 (33.33%) additional left renal arteries. In 1 block had bilateral additional renal arteries (Figure 2), in 3 blocks the additional artery was in the right side (Figure 3), and in 1 block, the additional renal artery was in the left side (Figure 4).

Among the 10% of the total sample that presented variations, 8% presented additional right renal artery, and 4%, additional renal artery on the left

side. The presence of bilateral additional renal arteries represents 2% of the total anatomical parts examined. Thus, 6% of the results obtained are unilateral right, 2% unilateral left, and 2% bilateral (Figure 1).

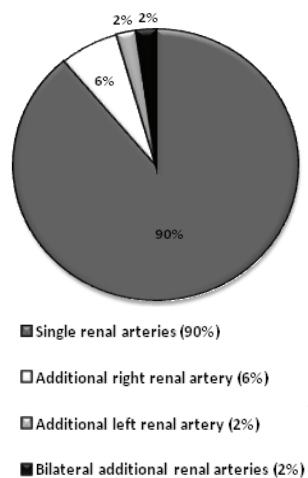


Figure 1. Distribution of the variation regarding the number of renal arteries.

Source: Research performed in anatomical parts of the Anatomy Laboratory of the State University of Maringá and Ingá Faculty.

In the block with bilateral variation, the accessory right renal artery is located anteriorly to the inferior vena cava; the accessory left renal artery is located anteriorly to a left renal vein. This block has also variation in the renal veins, which is being described in another study.

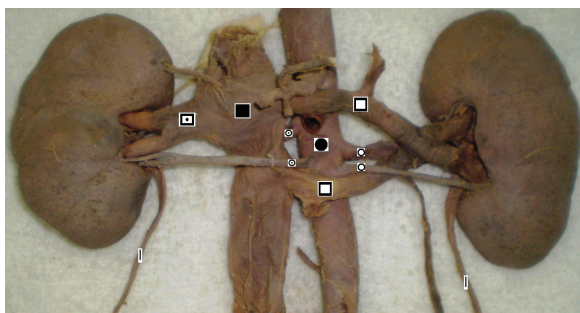


Figure 2. Anterior view of the anatomical part containing bilateral double renal arteries, and double renal veins on the left side.

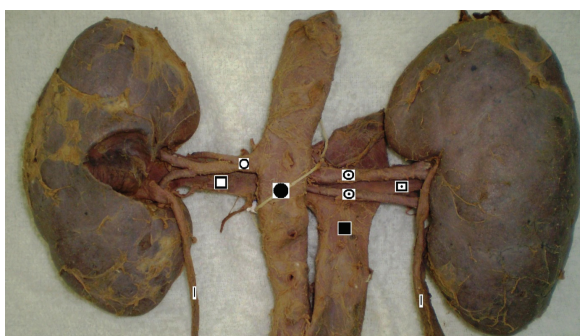


Figure 3. Posterior view of the anatomical part containing double right renal arteries.

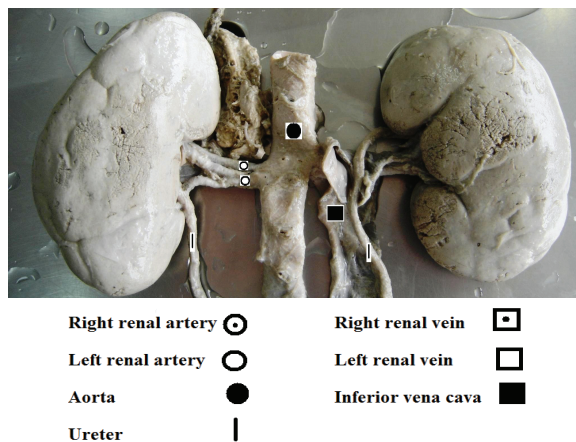


Figure 4. Posterior view of the anatomical part containing double left renal arteries.

Discussion

In our bibliographic survey it was possible to perceive no concordance in relation to nomenclature of additional renal arteries. For their description is used the following designations: additional renal arteries (NAYAK, 2008a; SILDARRIAGA et al., 2008a and b; SATYAPAL et al., 2001); extra renal arteries (ÖZKAN et al., 2006; SAMPAIO; PASSOS, 1992), multiple renal arteries (AYDIN et al., 2004; BENEDETTI et al., 1995; BUSATO; RIBAS, 2003; GAWISH et al., 2007; OLAVE, et al., 2007), accessory renal arteries (AUMÜLLER et al., 2009; BANERJEE et al., 2007; KARA et al., 2006; KEM et al., 2006; NAYAK, 2008a; NAYAK, 2008b; VILHOVA et al., 2001), double renal artery (BORDEI et al., 2004), supernumerary renal artery (NAYAK, 2008b; SHAKERI et al., 2007), aberrant renal artery (BANERJEE et al., 2007).

We agree with Satyapal et al. (2001) that highlight the need for a standard in nomenclature of these variations, which would assist in the accuracy of reports about the incidence of accessory renal arteries. In order to minimize this difficulty, the following definition of Satyapal et al. (2001) was adopted in the present study: 'an additional renal artery, other than the main renal artery, a vessel that arises from the aorta and ends in the kidney'.

It is classical the definition of accessory renal artery to indicate more than one renal artery that arises in separate branches of aorta or common iliac arteries. According to Banerjee et al. (2007), most of these arteries are smaller than the main renal artery, and the presence of a main renal artery with smaller diameter than normal is an indicative of the presence of an accessory renal artery.

The additional renal arteries usually arise from the aorta in a position upper or lower to the main renal artery directing to the renal hilum.

As the kidney develops, changes occur in the blood supply. When displaced to the lumbar region, the kidneys receive vascular supply from the caudal end of the aorta. During the ascension, they receive new branches from the aorta while the previous lower branches usually regress and disappear. When contacting the adrenal glands, the ascension ends. The permanent renal arteries arise from the more cranial branches received laterally of the abdominal aorta; the right renal artery is longer and upper than the left renal artery (MOORE; PERSUAD, 2008).

The additional arteries represent a trace of the kidney ascension from the pelvis to the lumbar region during the sixth up to the ninth week of gestation (KEM et al., 2006). Different origins of renal arteries and frequent variations were explained in the development of mesonephric arteries. These are formers of the supply network of kidneys, suprarenal glands, and gonads on both sides of the aorta between C6 and L3, a region known as urogenital arterial network. With the time, these arteries regress, remaining only one mesonephric artery, responsible for kidneys irrigation. Changes in the development of mesonephric arteries can result in more than one renal artery for each kidney (ÖZKAN et al., 2006).

When the location of the kidney is abnormal, the blood supply can be also abnormal, since this supply adapts according to the kidney location. These changes are associated with the anatomical position of each kidney in the embryonic development. The kidney development starts in the pelvic cavity with the kidneys ventrally near to the sacrum, supplied by the common iliac artery, and then it moves to the lumbar region around the ninth week, where it will be supplied by the abdominal aorta (MOORE; PERSUAD, 2008; NAYAK, 2008a and b; VILHOVA et al., 2001).

The kidneys are mainly irrigated by one pair of arteries originated from the aorta (70%). The presence of additional renal arteries is the most frequent variation, with prevalence between 25 and 30%. The frequencies of occurrence are: 1 additional artery: 17.6%; 2 additional arteries: 23%; and more than two additional arteries: 1% (KARA et al., 2006). Studies have observed 23% of the cases with two unilateral multiple arteries and 10% bilateral (GAWISH et al., 2007).

In our study, we found in 90% of the examined pieces 1 pair of renal arteries, and in 10%, additional renal arteries. This is a result similar to that of Busato and Ribas (2003) that verified an incidence of 10% of additional renal arteries. Nevertheless, the studies performed by Yetkin et al. (2008), Aydin et al. (2004), Dhar and Lal (2005) and Gawish et al. (2007), have registered approximately the double of cases.

Satyapal et al. (2001), Gawish et al. (2007) described the presence of bilateral multiple renal arteries in 10% of cases, opposing the 2% of our study that are closer to the 5% of bilateral additional renal arteries found by Dhar and Lal (2005).

The presence of bilateral single renal arteries in 90% of anatomical parts examined herein differs from Aydin et al. (2004) and Saldarriaga et al. (2008a), which observed 60 and 78.47% of single renal arteries, respectively.

Vilhova et al. (2001) reported the presence of multiple renal arteries in 25-30% on the left side. Satyapal et al. (2001) verified higher frequency of additional renal arteries on the left vascularization. These results do not corroborate our findings of 8% of the total with variation on the right renal vasculature and 4% with variations on the left side.

In the references used by Özkan et al. (2006) it was found that variations of renal arteries are common in the general population, being more frequent in Africans (37%), Caucasians (35%) than in Hindus (17%). The incidence of extra renal arteries shows variation from 9 to 76% (SHAKERI et al., 2007), usually between 28 and 30% in anatomical studies and with cadavers (ÖZKAN et al., 2006), different from the present study, where we observed double renal arteries in 10% of the anatomical parts.

Busato and Ribas (2003) observed in 90% of cases a single artery for each kidney. These authors also verified renal hypertension associated with multiple renal arteries in 80% of cases. Our findings showed that 90% of the blocks had a single renal artery. Moreover Moore and Persuad (2008) also refers that 75% of individuals presented a single renal artery for each kidney.

The existence of several renal arteries has been associated with the higher rate of vascular complications, also including thrombosis and arterial stenosis (BENEDETTI et al., 1995).

According to Nayak (2008a), the presence of 2 additional right renal arteries and 1 additional left renal vein can cause a compression on the renal pelvis, resulting in hydronephrosis (distension of the kidney by the urine, caused by the back pressure on the kidney when the flow is blocked). These views are partially confirmed by Vilhova et al. (2001), when asserting that the accessory renal artery, especially, when it emerges at lower position to the main renal artery, obstructs the ureter and may lead to hydronephrosis.

According to Banerjee et al. (2007) the ignorance of variations in the number of renal arteries in surgical interventions of aorta may result in

occlusion of renal artery leading to renal ischemic injury. Bordei et al. (2004) indicates an arteriography before any nephrectomy, since an accessory renal artery can double the chances of hemostatic failure.

Confirming the importance of the description of arterial variations Weber et al. (2009) mention on the need, for the surgeon, of radiographic images of renal vascularization to elucidate quantitatively the number of renal arteries present on each side. In general, the left side is usually preferred for transplantation because it has a longer vein, but if the left kidney has more than one renal artery, and the right kidney, only one; it is prudent to use the right kidney.

Conclusion

The anatomical variations, studied by numerous authors, are found in apparently normal individuals.

In the present study, we observed 5 anatomical parts with double renal arteries, which represents 10% of the total of examined parts.

The distribution of the 10% with variations is as follow: 6% of additional renal arteries only on the right side, 2% of additional renal arteries only on the left side and 2% of bilateral additional renal arteries.

The description and the knowledge of existing variations not only in renal arteries addressed here, but also in renal veins, help to plan and carry out safer surgical interventions, optimizing the process and reducing the risk of death of patients.

References

- AUMÜLLER, G.; AUST., G.; DOLL, A.; ENGELE, J.; KIRSCH, J.; MENSE, S.; REIBIG, D.; SALVETTER, J.; SCHMIDT, W.; SCHMITZ, F.; SCHULTE, E.; SPANEL-BOROWSKI, K.; WURZINGER, L. J.; ZILCH, H. G. **Anatomia**. 1. ed. Rio de Janeiro: Guanabara Koogan, 2009.
- AYDIN, C.; BERBER, I.; ALTACA, G.; YIGIT, B.; TITIZ, I. The outcome of kidney transplants with multiple renal arteries. **Biomed Central Surgery**, v. 4, n. 4, p. 1-3, 2004.
- BANERJEE, S.; CHO, M.; GUPTA, S.; BRILAKIS, E. S. Aberrant takeoff a right accessory renal artery, identified during an aortoiliac intervention. **Vascular Disease Management**, v. 4, n. 1, p. 4-5, 2007.
- BENEDETTI, E.; TROPPEMANN, C.; GILLINGHAM, K.; SUTHERLAND, D. E. R.; PAYNE, W. D.; DUNN, D. L.; MATAS, A. J.; NAJARIAN, J. S.; GRUSSNER, R. W. G. Short-and long- term outcomes of kidney transplants with multiple renal arteries. **Annals of Surgery**, v. 221, n. 4, p. 406-414, 1995.
- BORDEI, P.; SAPTE, E.; ILIESCU, D. Double renal arteries originating from the aorta. **Surgical Radiologic Anatomy**, v. 26, n. 6, p. 474-479, 2004.
- BUSATO, J. W. F. S.; RIBAS, F. J. M. Estudo da distribuição arterial em rins humanos. **Arquivos Catarinenses de Medicina**, v. 32, n. 3, p. 21-27, 2003.
- DHAR, P.; LAL, K. Main and accessory renal arteries - a morphological study. **The Internet Journal of Biological Anthropology**, v. 110, n. 2, p. 101-110, 2005.
- GAWISH, A. E.; DONIA, F.; SAMHAN, M.; HALIM, M. A.; AL-MOUSAWI, M. Outcome of renal allografts with multiple arteries. **Transplantation Proceedings**, v. 39, n. 4, p. 1116-1117, 2007.
- KADIR S. Kidneys. In: KADIR, S. (Ed.). **Atlas of normal and variant angiographic anatomy**. Philadelphia: W.B. Saunders Company, 1991. p. 387-429.
- KARA, A.; KURTOĞLU, Z.; OĞUZ, I.; ÖZTÜRK, A. H.; UZMANSEL, D. Two accessory renal arteries with histological properties. **Turkish Journal of Medical Sciences**, v. 36, n. 2, p. 133-138, 2006.
- KEM, D. C.; LYONS, D. F.; WENZL, J.; HALVERSTADT, D.; YU, X. Accessory renal arteries - mostly, but not always, innocuous: renin-dependent hypertension caused by nonfocal stenotic aberrant renal arteries - Proof of a new syndrome. **Journal of the American Society of Nephrology**, v. 17, p. 3-4, 2006.
- MOORE, K. L.; PERSUAD, T. V. N. **Embriologia clínica**. 8. ed. Rio de Janeiro: Elsevier, 2008. p. 250-254.
- NAYAK, B. S. Multiple variations of the right renal vessels. **Singapore Medicine Journal**, v. 49, n. 6, p. 153-155, 2008a.
- NAYAK, B. S. Presence of accessory renal artery and kinking of aorta due to the abnormal origin of renal arteries. **The Internet Journal of Biological Anthropology**, v. 1, n. 2, 2008b. Available from: <http://www.ispub.com/journal/the_internet_journal_of_biological_anthropology/volume_1_number_2_8/article/presence_of_accessory_renal_artery_and_kinking_of_aorta_due_to_the_abnormal_origin_of_renal_arteries.html>. Access on: July 13, 2010.
- OLAVE, E.; HENRÍQUEZ, J.; PUELMA, F.; CRUZAT, C.; SOTO, A. Arterias renales múltiples. **International Journal of Morphology**, v. 25, n. 4, p. 927-930, 2007.
- ÖZKAN, U.; OĞUZKURT, L.; TERCAN, F.; KIZILKILIÇ, O.; KOÇ, Z.; KOCA, N. Renal artery origins and variations: angiographic evaluation of 855 consecutive patients. **Diagnostic and Interventional Radiology**, v. 12, n. 4, p. 183-186, 2006.
- PUTZ, R.; PABST, R. **Sobotta atlas de anatomia humana**. 22. ed. Rio de Janeiro: Guanabara Koogan, 2006. p. 216.
- SALDARRIAGA, B.; PÉREZ, A. F.; BALLESTEROS, L. E. A direct anatomical study of additional renal arteries in a Colombian mestizo population. **Folia Morphologica**, v. 67, n. 2, p. 129-134, 2008a.
- SALDARRIAGA, B.; PINTO, S. A.; BALLESTEROS, L. E. Morphological expression of the renal artery. A direct anatomical study in a Colombian Half-castle population. **International Journal of Morphology**, v. 26, n. 1, p. 31-38, 2008b.
- SAMPAIO, F. J. B.; PASSOS, M. A. R. F. Renal arteries: anatomic study for surgical and radiological practice. **Surgical Radiologic Anatomy**, v. 14, n. 2, p. 113-117, 1992.

- SATYAPAL, K. S.; HAFJEJEE, A. A.; SINGH, B.; RAMSAROOP, L.; ROBBS, J. V.; KALIDEEN, J. M. Additional renal arteries: incidence and morphometry. **Surgical Radiologic Anatomy**, v. 23, n. 1, p. 33-38, 2001.
- SHAKERI, A. B.; TUBBS, R. S.; SHOJA, M. M.; PEZESHK, P.; FARAHANI, R. M.; KHAKI, A. A.; EZZATI, F.; SEYEDNEJAD, F. Bipolar supernumerary renal artery. **Surgical and Radiologic Anatomy**, v. 29, n. 1, p. 89-92, 2007.
- TESTUT, L.; JACOB, O. **Tratado de anatomia topográfica com aplicações médico cirúrgica**. 8. ed. Barcelona: Salvat, 1977.
- TESTUT, L.; LATAJET, A. **Tratado de anatomia humana**. 9. ed. Barcelona: Salvat, 1978.
- VILHOVA, I.; KRYVKO, Y. Y.; MACIEJEWSKI, R. The radioanatomical research of plural renal arteries. **Folia Morphologica**, v. 60, n. 4, p. 337-341, 2001.
- WEBER, E. C.; VILENSKY, J. A.; CARMICHAEL, S. W. **Netter: anatomia em imagens essencial**. 1. ed. Rio de Janeiro: Elsevier, 2009.
- YETKIN, U.; GÖKTOĞAN, T.; ERGÜNES, K.; SAHIN, A.; ERGENE, O.; GÜRBÜZ, A.; YÜREKLI, I. Renal artery duplication anomaly in our patients. **The internet journal of biological anthropology**, v. 2, n. 1, 2008. Available from: <http://www.ispub.com/journal/the_internet_journal_of_biological_anthropology/volume_2_number_1_8/article/renal_artery_duplication_anomaly_in_our_patients.html>. Access on: July 13, 2010.

Received on September 16, 2010.

Accepted on November 10, 2011.

License information: This is an open-access article distributed under the terms of the Creative Commons Attribution License, which permits unrestricted use, distribution, and reproduction in any medium, provided the original work is properly cited.