

Venom of the giant ant *Dinoponera quadricaps* attenuates inflammatory pain in mouse cutaneous wound healing model

Ana Maria Sampaio Assreuy^{1*}, Beatriz Lima Adjafre¹, Évillia Rayanne Oliveira Sousa¹, Ana Paula Negreiros Nunes Alves², Alana de Freitas Pires¹, Yves Quinet¹ and Mário Rogério Lima Mota²

¹Instituto Superior de Ciências Biomédicas, Universidade Estadual do Ceará, Av. Dr. Silas Munguba, 1700, 60714-903, Itaperi, Fortaleza, Ceará, Brazil.

²Departamento de Clínica Odontológica, Faculdade de Farmácia, Odontologia e Enfermagem, Universidade Federal do Ceará, Fortaleza, Ceará, Brazil.

*Author for correspondence. E-mail: anassreuy@gmail.com

ABSTRACT. Arthropod venoms are potential sources of bioactive substances, providing tools for the validation of popular use and new drugs design. Ants belonging to the genus *Dinoponera* are used in the folk medicine to treat inflammatory conditions. It was previously demonstrated that the venom of the giant ant *Dinoponera quadricaps* (DqV), containing a mixture of polypeptides, elicit antinociceptive effect in mice models of chemical, mechanical and thermal nociception. The aim of this study was to evaluate DqV antiinflammatory and antihypernociceptive effects in a mice model of traumatic cutaneous wound. Colonies of *D. quadricaps* were collected in the “Serra de Maranguape” (State of Ceará, northeastern Brazil), a small mountain range located on the coastal zone, and the venom secreted by the ant glands was extracted with capillary tubes, further lyophilized and maintained at $-20 \pm 1^\circ\text{C}$ until use. Wounds were performed in the dorsum of Swiss mice. Animals received intravenous (i.v.) injection of DqV ($50 \mu\text{g kg}^{-1}\text{day}^{-1}$) during 3 days for evaluation of inflammatory parameters present in the wounds: hypernociception, leukocyte infiltrate, myeloperoxidase activity, nitrite nitrate⁻¹ content. Data was tested by two-way ANOVA and Bonferroni’s post-hoc test. DqV reduced (2.7 folds) hypernociception at 48 hours, leukocyte infiltration by 65% at 6 hours and myeloperoxidase activity by 60% at 0.5 hour after wound induction. In conclusion, the venom extracted from *D. quadricaps* glands attenuates inflammation and hypernociception in mice cutaneous wounds.

Keywords: DqV; Hypernociception; Leukocyte infiltrate; Scar.

Received on April 30, 2019.

Accepted on July 25, 2019.

Introduction

In Brazilian folk medicine, ants belonging to the genus *Dinoponera* (Formicidae: Ponerinae) are used to treat inflammatory conditions: the ant sting for rheumatism by indigenous population (Haddad Junior, Amorim, Haddad Junior, & Cardoso, 2015) and the macerate of the entire ant for ear ache (Costa Neto, 2011). The venom gland in the sting apparatus of *Dinoponera quadricaps* produces a venom that contains *Dinoponera* toxins (DnTx), pilosulin-like toxins, ICK-folded toxins, lethal-like toxins, allergen proteins and esterases (phospholipases and carboxylesterases) (Torres et al., 2014; Mariano et al., 2019). Experimental studies using the crude venom of *D. quadricaps* (DqV) demonstrated antinociceptive effect in mice models of chemical, mechanical and thermal nociception (Sousa et al., 2012). Other pharmacological properties were also demonstrated for DqV, such as antimicrobial (Lima et al., 2014), antiplatelet, anticoagulant (Madeira et al., 2015), pro- and anti-inflammatory (Sousa et al., 2016), and pro- and anticonvulsant (Nôga et al., 2015).

Based on the popular use of *Dinoponera* ants as analgesic and anti-inflammatory, along with the experimental results with DqV in mice models of nociception, the aim of this study was to evaluate its anti-inflammatory and antinociceptive effects in a model of traumatic cutaneous wound.

Material and methods

Material

Colonies of *D. quadricaps* Santschi, 1921 were collected (SISBIO authorization 28794-1) in the “Serra de Maranguape” (State of Ceará, northeastern Brazil), a small mountain range located on the coastal zone, and

maintained at the Laboratory of Entomology (*Universidade Estadual do Ceará*). The venom secreted by the ant glands was extracted with capillary tubes, lyophilized and maintained at $-20 \pm 1^{\circ}\text{C}$ until use (Sousa et al., 2012).

Female Swiss mice (22-35 g), maintained at $26 \pm 1^{\circ}\text{C}$ under a 12/12 hours light dark cycle and receiving food and water *ad libitum*, were brought to the laboratory 1 hour before the experiments, that were conducted according to protocols approved by our institutional Animal Care and Use Committee (CEUA/UECE 1776865/2015) and international principles (NIH publication #85-23, revised in 2011).

Wound model

For wound induction, animals were anesthetized by intraperitoneal (i.p.) route with 10% ketamine (1.25 mL kg^{-1}) and 2% xylazine (0.652 mL kg^{-1}). After dorsum shaving and antisepsis with 70% ethanol, two circular full-thickness wounds were performed using biopsy punch of 7 mm diameter (ABC Instrumentos Cirúrgicos, Brazil), followed by excision of epidermis, dermis and hypodermis to expose the panniculus carnosus (Pereira et al., 2016). Twenty-four hours after ulceration, animals received intravenous (i.v.) injection of sterile saline as control, celecoxib (Celebra®, 30 mg kg^{-1}) as reference drug, or DqV at $50 \mu\text{g kg}^{-1}$ (dose of maximal antinociceptive effect) (Sousa et al., 2012) for 3 days, once a day. After intervals of 0.5, 1, 6, 12, 24 - 96 hours, wounds were excised for quantification of myeloperoxidase activity (MPO) (Bradley, Priebat, Christensen, & Rothstein, 1982), nitrite nitrate⁻¹ content (Green et al., 1982), polymorphonuclear leukocyte infiltrate and hypernociception.

Leukocyte infiltrate

Skin fragments were fixed for 24 hours in 10% formaldehyde, subjected to dehydration in an increasing alcohol series, cleared in xylol, embedded in paraffin (60°C), sectioned in microtome ($5 \mu\text{m}$ thickness) and stained with hematoxylin and eosin (H&E). Five fields were selected per slide in areas close to the ulcer presenting high cell density. Polymorphonuclear cells (segmented nucleus cells with multilobulated nucleus morphology per field) were quantified by optical microscopy (1000x) (Andrade et al., 2011). The sample unit for each animal was the sum of 5 fields per slide.

Hypernociception

Hypernociception was measured in grams (g) using the analgesiometer (Insight Equipamentos, Brasil), composed of a pressure transducer connected to a digital counter. The mechanical pressure (polypropylene tip - 0.5 mm diameter) was applied to ulcer edges as nociceptive stimuli, being expressed as frequency of the behavioral responses (squeaking and writhing). The nociceptive threshold (average of three values) was measured prior to ulceration and after DqV treatment at 0.5, 1, 6, 12, 24, 48 and 72 hours (Pereira et al., 2016), and expressed as the area under the curve (AUC).

Statistical analysis

Results were expressed as mean \pm SEM and tested by two-way Analysis of Variance (ANOVA) followed by Bonferroni's post-hoc test. Statistical significance was set at $\alpha = 0.05$.

Results and discussion

The present study demonstrated that DqV inhibits the nociceptive behavior and the number of polymorphonuclear leukocytes at the inflammatory stage of the healing process, corroborating the popular use in inflammatory and painful conditions (Haddad et al., 2015).

The three-day treatment with DqV ($50 \mu\text{g kg}^{-1} \text{ day}^{-1}$; i.v) brought the nociceptive threshold at the wound margins to control values. The antinociceptive effect of DqV (300 AUC) started 30 min after injection and was maintained until the 2nd day of treatment (48 hours) compared to saline (AUC: 100). The reference drug celecoxib was also antinociceptive (AUC: 200) (Figure 1A/B). Although DqV had inhibited nociception in the wound area at several stages of healing (0.5 until 48 hours), it only decreased by 65% the number of polymorphonuclear cells at 0.5 and at 6h post-treatment (Figure 1C and Figure 2). These data suggest that DqV antinociceptive effect could be associated to the inhibition of inflammatory cells and nociceptive mediators.

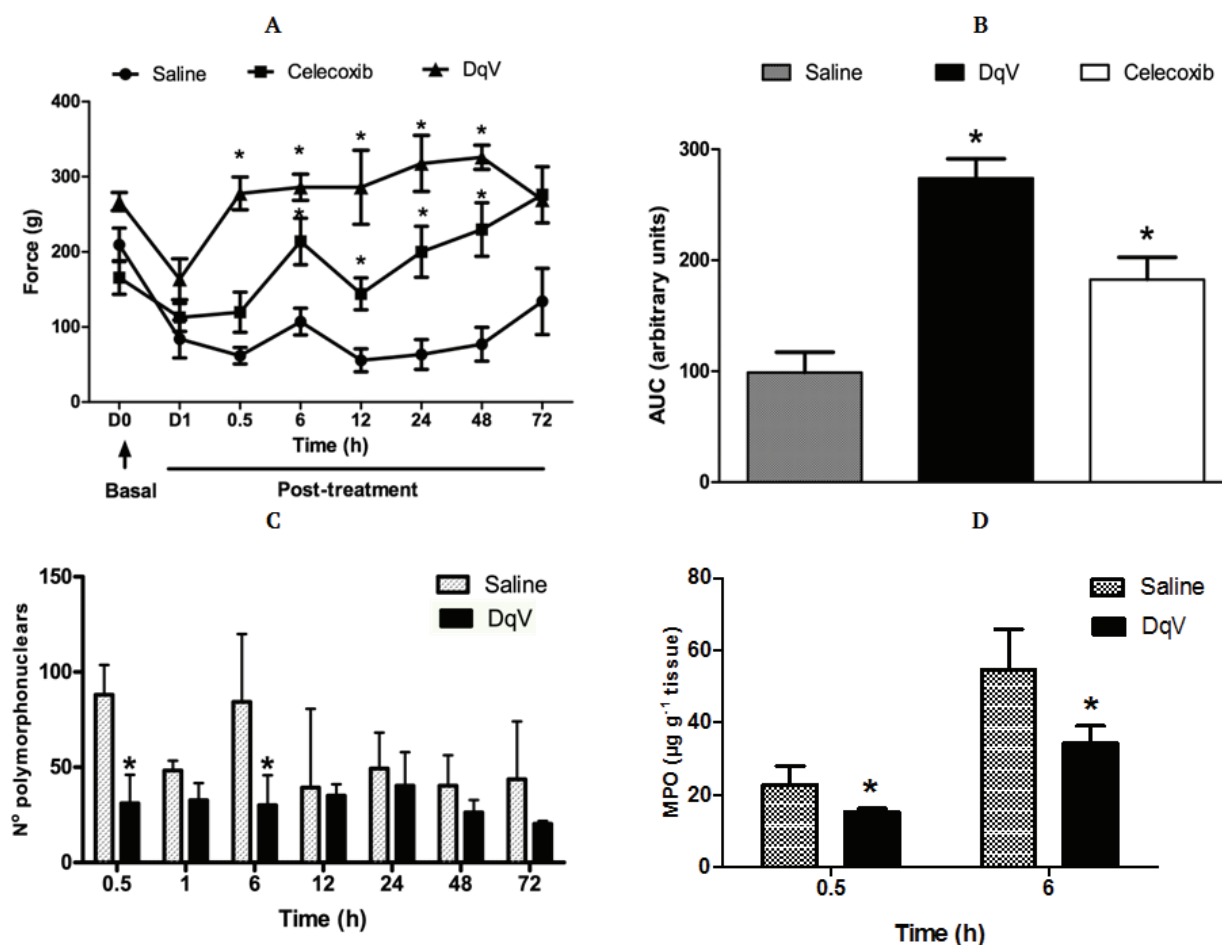


Figure 1. DqV inhibits hyperalgesia in excisional wounds in mice. Animals received i.v. DqV ($50 \mu\text{g kg}^{-1} \text{ day}^{-1}$), saline or celecoxib ($30 \text{ mg kg}^{-1} \text{ day}^{-1}$) for 3 days 24 hours after ulceration (D1). Nociception ($n=6 \text{ time}^{-1}$) was measured by pressure application on the wound margins: (A) Time course; (B) Area under the curve (AUC). Wounds ($n=3-5 \text{ time}^{-1}$) were excised for quantification of polymorphonuclear cells (C) and MPO activity (D). Mean \pm SEM. Two-way ANOVA and Bonferroni's test. * $p < 0.05$ vs. saline.

Our data are in line with the literature, since cutaneous wounds, such as those caused by pressure, venous insufficiency, neuropathy, or arterial disease, may evoke considerable pain (Young & McNaught, 2011). Besides, during the healing inflammatory phase, several cellular mediators are released, primarily by neutrophils and macrophages, in order to clean the wound site of cellular debris and pathogens and to attract other cells accounted for closing the wound (Patel, Maheshwari, & Chandra, 2016). These mediators, such as cytokines (interleukins, tumor necrosis factor, etc.), arachidonic acid by-products (prostaglandins), reactive species (hydrogen peroxide, superoxide anion, nitrate, etc.) and enzymes (MPO, nitric oxide synthase, etc.) are also involved in the genesis of pain, signaling to the nociceptor (Singh, Kumar, & Vinayak, 2018). Accordingly, Dqv inhibition on leukocyte infiltrate was confirmed by the inhibition of MPO activity at 0.5 ($12.8 \mu\text{g mg}^{-1} \text{ tissue}$) and 6 hours ($30 \mu\text{g mg}^{-1} \text{ tissue}$), by 60% and 48%, respectively (Figure 1D). However, DqV did not alter the nitrite/nitrate content (0.5h: 5.17 ± 0.28 vs. saline: $5.14 \pm 0.29 \mu\text{M}$; 6h: 5.05 ± 0.2 vs. saline: $5.49 \pm 0.08 \mu\text{M}$). This parameter is a feature of acute inflammation, being involved in vascular alterations, such as vasodilatation and augment of vascular permeability (Patel et al., 2016). The lack of DqV effect on the nitrate content could be seen as beneficial, considering the dual role of NO in the inflammatory response, being toxic to infectious organisms and/or to host tissues or acting as antiinflammatory agent (Bogdan, 2001).

The present study is in accordance with the literature that show antinociceptive and antiinflammatory activities of other *Hymenoptera* venoms, such as bee venom constituents (Bogdan, 2001; Lee & Bae, 2016) and ant venoms (Yoon et al., 2015; Altman et al., 1984), including those of *D. quadricaps* (Sousa et al., 2012). In this line, the novel data concerning the antiinflammatory and antinociceptive effects of DqV on traumatic wounds in mice open new and better possibilities for wound care.

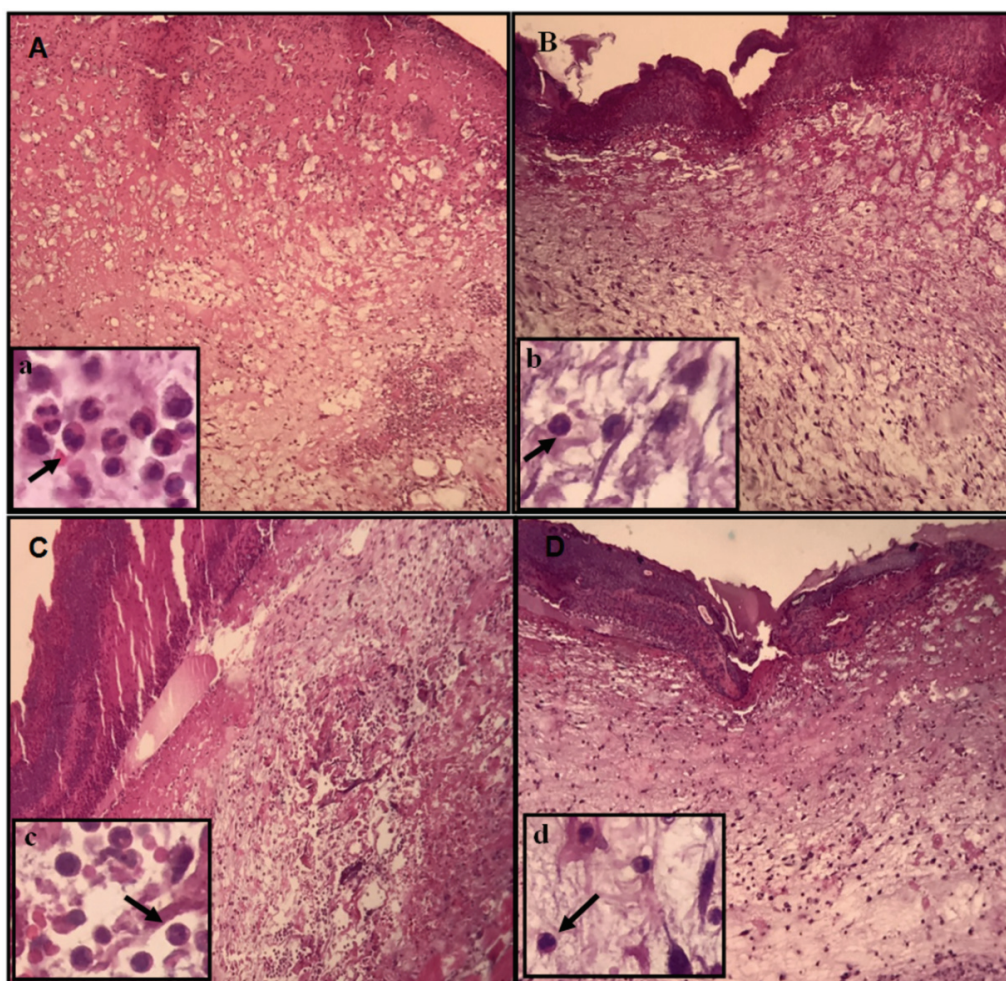


Figure 2. Cutaneous wounds photomicrography of mice treated with DqV. Animals received i.v. saline (A, C) or DqV ($50 \mu\text{g kg}^{-1} \text{ day}^{-1}$) (B, D) for 3 days. Wounds were removed for histological analysis after 30 min. (A, B) and 6h (C, D) of treatment. Inflammatory infiltrate of polymorphonuclear cells (arrow); H&E; A, B, C, D (200x); a, b, c, d (600x).

Conclusion

The venom extract of *D. quadricaps* glands attenuates inflammation and hypernociception in traumatic cutaneous wounds of mice.

Acknowledgements

This work was supported by *Fundação Cearense de Apoio ao Desenvolvimento Científico e Tecnológico* (FUNCAP) and *Conselho Nacional de Desenvolvimento Científico e Tecnológico* (CNPq).

References

- Altman, R. D., Schultz, D. R., Collins-Yudiskas, B., Aldrich, J., Arnold, P. I., & Brown, H. E. (1984). The effects of a partially purified fraction of an ant venom in rheumatoid arthritis. *Arthritis and Rheumatism*, 27(3), 277-284. doi: 10.1002/art.1780270305
- Andrade, T. A., Iyer, A., Das, P. K., Foss, N. T., Garcia, S. B., Coutinho-Netto, J., ... Frade, M. A. (2011). The inflammatory stimulus of a natural latex biomembrane improves healing in mice. *Brazilian Journal of Medical and Biological Research*, 44(10), 1036-1047. doi: 10.1590/S0100-879X2011007500116.
- Bogdan, C. (2001). Nitric oxide and the immune response. *Nature Immunology*, 2(10), 907-916. doi: 10.1038/ni1001-907
- Mariano, D. O. C., Oliveira, Ú. C., Zaharenko, A. J., Pimenta, D. C., Rádis-Baptista, G., & G., Prieto-da-Silva, Á. R. B (2019). Bottom-up proteomic analysis of polypeptide venom components of the giant ant *Dinoponera quadricaps*. *Toxins (Basel)*, 11(8), 448. doi: 10.3390/toxins11080448

- Bradley, P. P., Priebat, D. A., Christensen, R. D., & Rothstein, G. (1982). Measurement of cutaneous inflammation: estimation of neutrophil content with an enzyme marker. *The Journal of Investigative Dermatology*, 78(3), 206-209. doi: 10.1111/1523-1747.ep12506462
- Costa Neto, E. M. (2011). The popular zootherapy in Bahia state: registration of new animal species used as medicinal resources. *Ciência & Saúde Coletiva*, 16(1), 1639-1650. doi: 10.1590/S1413-81232011000700100
- Green, L. C., Wagner, D. A., Glogowski, J., Skipper, P. L., Wishnok, J. S., & Tannenbaum, S. R. (1982). Analysis of nitrate, nitrite, and [15N] nitrate in biological fluids. *Analytical Biochemistry*, 126(1), 131-138. doi: 10.1016/0003-2697(82)90118-X
- Haddad Junior, V., Amorim, P. C. H., Haddad Junior, W. T., & Cardoso, J. L. C. (2015). Venomous and poisonous arthropods: identification, clinical manifestations of envenomations, and treatments used in human injuries. *Revista da Sociedade Brasileira de Medicina Tropical*, 48(6), 650-657. doi: 10.1590/0037-8682-0242-2015
- Lee, G., & Bae, H. (2016). Bee venom phospholipase A2: yesterday's enemy becomes today's friend. *Toxins (Basel)*, 8(2), 48. doi: 10.3390/toxins8020048
- Lima, D. B., Torres, A. F. C., Mello, C. P., Menezes, R. R. P. B., Sampaio, T. L., Canuto, J. A., ... Martins, A. M. C. (2014). Antimicrobial effect of *Dinoponera quadricaps* (Hymenoptera: Formicidae) venom against *Staphylococcus aureus* strains. *Journal of Applied Microbiology*, 117(2), 390-396. doi: 10.1111/jam.12548
- Madeira, J. C., Quinet Y. P., Nonato, D. T. T., Sousa, P. L., Chaves, E. M. C., Honório Júnior, J. E. R., ... Assreuy A. M. S. (2015). Novel pharmacological properties of *Dinoponera quadricaps* giant ant venom. *Natural Product Communications*, 10(9), 1607-1609. doi: 10.1177/1934578X1501000930
- Nôga, D. A., Cagni, F. C., Santos, J. R., Silva, D., Azevedo, D. L., Araújo, A., ... Ribeiro, A. M. (2015). Pro- and anticonvulsant effects of the ant *Dinoponera quadricaps* (Kempf) venom in mice. *Neotropical Entomology*, 44(4), 410-417. doi: 10.1007/s13744-015-0292-7
- Patel, S., Maheshwari, A., & Chandra, A. (2016). Biomarkers for wound healing and their evaluation. *Journal of Wound Care*, 25(1), 46-55. doi: 10.12968/jowc.2016.25.1.46
- Pereira, L. P., Mota, M. R., Brizenno, L. A., Nogueira, F. C., Ferreira, E. G., Pereira, M. G., & Assreuy, A. M. (2016). Modulator effect of a polysaccharide-rich extract from *Caesalpinia ferrea* stem barks in rat cutaneous wound healing: Role of TNF- α , IL-1 β , NO, TGF- β . *Journal of Ethnopharmacology*, 187, 213-223. doi: 10.1016/j.jep.2016.04.043
- Singh, A. K., Kumar, S., & Vinayak, M. (2018). Recent development in antihyperalgesic effect of phytochemicals: anti-inflammatory and neuro-modulatory actions. *Inflammation Research*, 67(8), 633-654. doi: 10.1007/s00011-018-1156-5
- Sousa, P. L., Quinet, Y., Ponte, E. L., Vale, J. F., Torres, A. F., Pereira, M. G., & Assreuy, A. M. (2012). Venom's antinociceptive property in the primitive ant *Dinoponera quadricaps*. *Journal of Ethnopharmacology*, 144(1), 213-216. doi: 10.1016/j.jep.2012.08.033
- Sousa, P. L., Quinet, Y. P., Brizenno, L. A. C., Sampaio, T. L., Torres, A. F., Martins, A. M., & Assreuy, A. M. (2016). The acute inflammatory response induced in mice by the venom of the giant ant *Dinoponera quadricaps* involves macrophage and interleukin-1 β . *Toxicon*, 117, 22-29. doi: 10.1016/j.toxicon.2016.03.009
- Torres, A. F., Huang, C., Chong, C. M., Leung, S. W., Prieto-da-Silva, A. R., Havt, A., ... Rádis-Baptista, G. (2014). Transcriptome analysis in venom gland of the predatory giant ant *Dinoponera quadricaps*: insights into the polypeptide toxin arsenal of hymenopterans. *PLoS One*, 9(1), e87556. doi: 10.1371/journal.pone.0087556
- Yoon, H., Kim, M. J., Yoon, I., Li, D. X., Bae, H., & Kim, S. K. (2015). Nicotinic acetylcholine receptors mediate the suppressive effect of an injection of diluted bee venom into the GV3 acupoint on oxaliplatin-induced neuropathic cold allodynia in rats. *Biological & Pharmaceutical Bulletin*, 38(5), 710-714. doi: 10.1248/bpb.b14-00797
- Young, A., & McNaught, C.-E. (2011). The physiology of wound healing. *Surgery Oxford*, 29(10), 475-479. doi: 10.1016/j.mpsur.2011.06.011