



Evidence of cytogenetic and histological damage in specimens of *Astyanax lacustris* (Pisces, Characidae) exposed to the hydrogen cyanide-based herbicide Dormex®

Layon Zafra-Lemos^{1*}, Vera Lúcia Lopes¹, Ana Paula de Santi Rampazzo², Maria Raquel Marçal Natali², Luciana Andreia Borin-Carvalho¹ and Ana Luiza Brito Portela-Castro¹

¹Departamento de Biotecnologia, Genética e Biologia Celular, Universidade Estadual de Maringá, Av. Colombo, 5790, 87020-900, Maringá, Paraná, Brazil.

²Departamento de Ciências Morfológicas, Universidade Estadual de Maringá, Maringá, Paraná, Brazil. *Author for correspondence. E-mail: layonzafra@hotmail.com

ABSTRACT. The herbicide Dormex®, a solution of hydrogen cyanamide, is a growth regulator capable of breaking the dormancy of fruit plants, and is commonly applied in agriculture. However, the biological effects of this product on non-target organisms are unknown. The present study investigated the biological response of *Astyanax lacustris* (Lütken, 1875) specimens exposed to Dormex® using a chromosome aberration test, the mitotic index, and the histological analysis of the gills. Forty specimens of *Astyanax lacustris* were obtained from a local breeding facility and divided into 10 groups (nine experimental and one control) with four fish in each aquarium (group). The control group was maintained for 24 hours in dechlorinated water while the experimental groups were allocated to one of nine different treatments, with three concentrations of Dormex®, 0.05, 0.1 and 0.5 mL L⁻¹, and exposure for 24, 48 and 72 hours. The fish exposed to Dormex® presented chromosomal aberrations of a number of types, including chromosomal breaks, acentric fragments, decondensation, and gaps at the three Dormex® concentrations, at all exposure times. The mitotic index decreased significantly in comparison with the control group. The histological preparations of the gills revealed alterations such as hyperplasia, and lamellar fusion and edema, whereas in the control group the structure of the gills was preserved. The cytogenetic analysis revealed the genotoxic potential of the herbicide Dormex® and the morphological alterations of the gills demonstrated the sensitivity of the fish, which responded rapidly to the stressor. These findings reinforce the need for special care and restrictions on the use of these herbicides in agricultural areas located near aquatic environments.

Keywords: pesticides; chromosomal aberrations; biomarkers; fish; hyperplasia; lamellar fusion.

Received on December 12, 2019.

Accepted on September 16, 2020.

Introduction

Agrochemicals, such as fertilizers, herbicides and pesticides, are widely used in many countries to increase agricultural productivity. Since the turn of the 21st Century, the need to feed the world's rapidly growing population has maintained pressure on farmers to depend increasingly on the application of pesticides and fertilizers (Carvalho, 2017). However, the intensive use of these agrochemicals has been a major concern for the many scientists who have documented the negative effects of these agrochemicals, including disease, food poisoning, and environmental contamination (Alavanja, 2009; Nicolopoulou-Stamati, Maipas, Kotampasi, Stamatis, & Hens, 2016; Pignati et al., 2017).

Brazil is currently one of the world's major suppliers of agricultural products, and depends heavily on production-enhancing strategies, such as the planting of transgenic seeds and the application of chemical compounds, including fertilizers and pesticides (Pignati et al., 2017). The application of different agrochemicals varies by region, and in tropical regions, in particular, where insect pests and plant diseases tend to be more prevalent, pesticides may be applied in enormous quantities (Carvalho, 2006). The lack of cold weather in the tropical zone may also prevents the breaking of the dormancy of some temperate plant species, which may require the application of specific chemicals to ensure that dormancy is broken (Segantini, Leonel, Ripardo, Tecchio, & Souza, 2015). Growth regulators are a class of herbicides used to break dormancy in fruit plants, and one of these compounds, Dormex®, is used to stimulate and standardize budding and flowering in temperate species. The active ingredient of this herbicide is hydrogenated cyanamide, an organic compound applied in agriculture (Soltys et al., 2011), which is an efficient plant growth regulator, has been

used in agriculture in many regions of Brazil, where it is applied in doses ranging from 0.6 to 7% (registered at the *Ministério da Agricultura, Pecuária e Abastecimento* - Mapa, N° 001095), depending on the crop. However, it is also highly toxic and exposure to this chemical is hazardous, requiring the use of adequate safety protocols by farmworkers applying it to crops, according to manufacturer's instructions.

The toxicity of many pesticides and herbicides in non-target, aquatic organisms, such as fish, has been well documented. Solomon, Dalhoff, Volz, and Kraak (2013), reviewed the evidence on the effects of different classes of herbicides and their mode of action in fish. Fish are also a useful genetic model for the assessment of pollution in aquatic ecosystems, based on genotoxicity and mutagenicity tests, which may include the sister chromatid exchange and chromosomal aberrations tests, micronucleus and comet assays, and DNA repair synthesis (Cavaş & Könen, 2007; Saxena & Chaudhari, 2010; Mohanty, Mohanty, Nayak, Mohanty, & Dutta, 2011; Yadav, Bhatnagar, & Kaur, 2013). These biomarkers present a clear response to the genotoxic damage caused by herbicides in fish, which may lead to reduced survival, growth, and reproduction (Samanta, Kumari, Pal, Mukherjee, & Ghosh, 2018).

The analysis of the tissue of organs that come into direct contact with toxic agents, such as the gills, or those that metabolize (liver) or excrete (kidneys) xenobiotic compounds can provide clear evidence of toxic effects (Lins, Kirschnik, Queiroz, & Cirio, 2010). These histopathological indicators provide an important tool for the assessment of the health of fish (Schwaiger et al., 1997; Rašković et al., 2013; Samanta et al., 2018). Tabassum et al. (2016) for example, found significant alterations in the histology of the gills, kidney, and liver of *Channa punctata* (Bloch, 1793) specimens exposed to a fungicide (Propiconazol®) including primary and secondary atrophy and inflammation of the gill lamellae, hepatocyte degeneration, vacuolization, and necrotic renal tissue. The histopathological analysis of fish tissue thus permits the identification of early signs of disease, and contributes to the understanding of stress responses (Dane & Şişman, 2017).

Studies on the genetic and histological damage in fish exposed to Dormex® are practically nonexistent, therefore, in the present study we evaluated the potential toxic effects of Dormex® on *Astyanax lacustris* (Lütken, 1875) in kidney cells using the chromosomal aberration test, the mitotic index, and the histological analysis of gill sections.

Material and methods

Herbicide characteristics

Dormex® is a commercial solution composed of 520 of hydrogenated cyanamide (52%) and 545 g L⁻¹ (54.5%) of other ingredients (Degussa AG - Alemanha), as registered at the *Ministério da Agricultura, Pecuária e Abastecimento* (Mapa, N° 001095).

Experimental groups

Astyanax lacustris is a fish species widely distributed in the upper Paraná River basin (Lucena & Soares, 2016). While not exploited as a food species, it is ecologically important as an item in the diets of commercially-important piscivores (Silva, Pessoa, Costa, Chellappa, & Chellappa, 2012). Adult specimens with a mean weight of 9±11 g and length of 9±15 cm were obtained from a local breeding facility. The fish were acclimatized in aquaria with dechlorinated water at room temperature, constant aeration, and natural photoperiod (12:12 light/dark cycle) for 10 days in the Sectoral Vivarium for Fish Keeping and Experimentation at *Universidade Estadual de Maringá* (UEM) in Maringá, Paraná state, Brazil.

Forty specimens were divided into 10 groups, one control and nine experimental, containing n = 4 individuals per group. Number of fish per aquarium it was established according to the body mass/water volume ratio that should not exceed 0.5-2 g L⁻¹ (Concea Guide, Annex I, Fish). In the control group, the fish were kept in dechlorinated water for 24 hours. In each experimental group, the fish were exposed to Dormex® solution at concentrations of 0.05, 0.1 and 0.5 mL L⁻¹ dissolved in 10 L of water during 24, 48 and 72 hours for each concentration, corresponding to an acute test. Fish euthanasia procedures were performed according to Inoue and Moraes (2007), for removal of the gills and kidneys.

Choromosome preparation

Mitotic chromosomes were obtained from the kidney cells following the technique proposed by Bertollo, Takahashi, and Moreira Filho (1978). The nucleolus organizer regions (NORs) were detected by impregnation with silver nitrate (Ag-NO₃), according to the technique of Howell and Black (1980). Constitutive

heterochromatin was detected by the C-banding technique, as described in Sumner (1972), and stained with propidium iodide according to the method of Lui, Blanco, Margarido, and Moreira-Filho (2009). Some metaphases were stained with a base-specific fluorochrome, DAPI (4',6-diamidino-2-phenylindole), which identifies chromosomal regions rich in AT bases (Schweizer, 1980). For the analysis of chromosomal aberrations, 60 metaphases were obtained per concentration of the Dormex® solution and 60 from the control group, for a total of 240 metaphases. The metaphases were analyzed under an optical microscope (Olympus) and photographed with an epifluorescence microscope (Axioskop, Zeiss) equipped with a digital camera coupled to an image-capture system. The Mitotic Index (MI) was calculated for a total of 4,000 cells per group, as follows: $MI (\%) = (\text{number of cells in division} / \text{total number of cells}) \times 100$ (Umar-Tsafe, Mohamed-Said, Rosli, Din, & Lai, 2004).

Histological analysis

Samples of the gill tissue were fixed in Bouin's aqueous solution during 6 hours (Behmer, Tolosa, & Freitas Neto, 1976), and then stored in 70% alcohol. For histological processing, the material was dehydrated in an increasing series of alcohol (80, 90 and 100%), diaphanized in xylol, and embedded in paraffin. Semi-serial cross-sections of 6 µm in thickness were obtained using a Leica rotating microtome at the Laboratory of Animal Histotechnology of the Morphological Sciences Department of *Universidade Estadual de Maringá* (UEM). The slides were stained by the Hematoxylin-Eosin (HE) method (Behmer et al., 1976). For the morphological analysis and verification of gill abnormalities, 30 random fields were observed per animal under light microscopy (Olympus CX31RBSFA) with 20 and 40X objectives, following the semiquantitative protocol of Schwaiger et al. (1997) and a quantitative search for lamellar aneurysms. A Mean Change Value (M.C.V.) analysis was established, according to the degree of severity of the lesions, as described by Mallatt (1985).

Ethical aspects

The experimental procedures were performed in accordance with Ethics Committee for the Use of Animals in Research (CEUA, license number 3574220517).

Statistical analysis

The mitotic index and histological data, expressed as the means \pm standard deviation were evaluated for normality using the Kolmogorov-Smirnov test. The variation in the mitotic index was evaluated using a one-way Analysis of Variance (ANOVA) followed by Dunnett's test for multiple comparisons. The histological data were also analyzed by a one-way ANOVA, followed by the Tukey test. A 5% significance level was considered in all analyses. The graphs were plotted in GraphPad Prism 5.

Results and discussion

Cytogenetic analysis

The fish exposed to the herbicide Dormex® presented chromosomal aberrations (CAs) at all concentrations tested. A total of 240 metaphases (60 metaphases per group, including the control) were obtained from the *A. lacustris* specimens. In the control group, the majority of metaphases ($2n = 50$) had no changes in their chromosome structure (Figure 1A). In the herbicide treatment groups, the number of metaphases with CA (a total of 12) did not vary significantly among treatments or exposure times, with five being recorded at a concentration of 0.05, three at 0.01, and four at 0.5 mL L⁻¹. Despite the low Dormex® concentrations applied in the present study, the presence of chromosomal aberrations in all three groups indicates the toxic effects of this compound on the fish. In addition, some metaphases presented more than one chromosome with aberrations (Figure 1B-F).

The mitotic index (MI) of the kidney cells varied significantly ($p < 0.05$) among Dormex® concentrations and exposure times (Table 1, Figure 2), with a reduction in the number of kidney cells in mitosis in comparison with the control group (2.10 to 0.47). These results indicate that Dormex® may interfere with cell division in the cells of *A. lacustris*. There was also a significant reduction in MI as exposure time increased in the 0.05 and 0.1 mL L⁻¹ groups. At the higher concentration (0.5 mL L⁻¹), however, an inverse relationship was found with exposure times, which may reflect a reduction in the concentration of the cyanamide in the water over time, which may have allowed for the recovery of the animals, or alternatively, an increase in the effectiveness of DNA repair mechanisms over time.

Understanding the DNA repair mechanisms in a target species is of fundamental importance, given that this is the main line of defense of an organism against genotoxic agents (Kienzler, Bony, & Devaux, 2013). Srivastava and Singh (2013), found that the mitotic index was significantly ($p < 0.05$) reduced in the kidney tissue of specimens of the walking catfish, *Clarius batrachus* (Linnaeus, 1758), exposed to sub-lethal doses of carbamate fungicide (11.43 and 22.87 mg L⁻¹), after 24, 48, 72 and 96 hours.

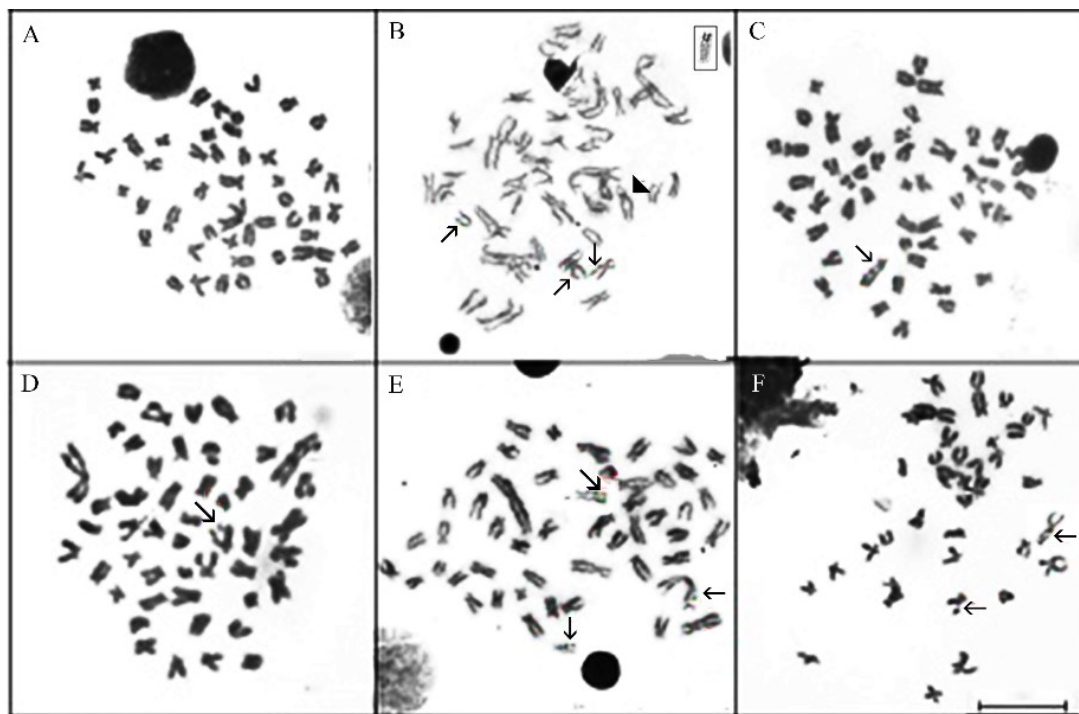


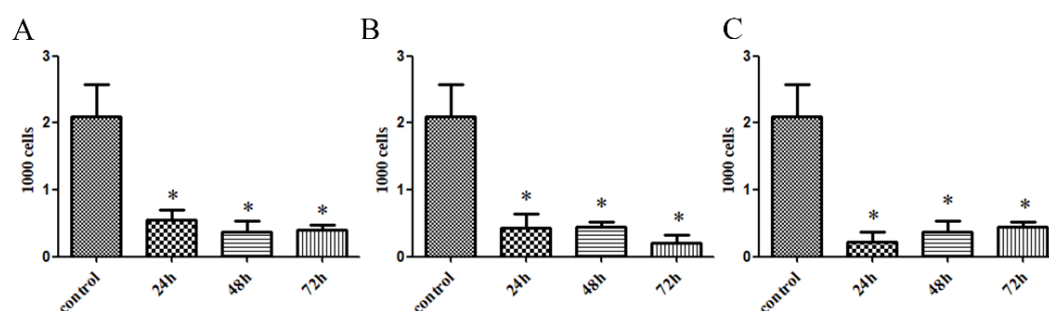
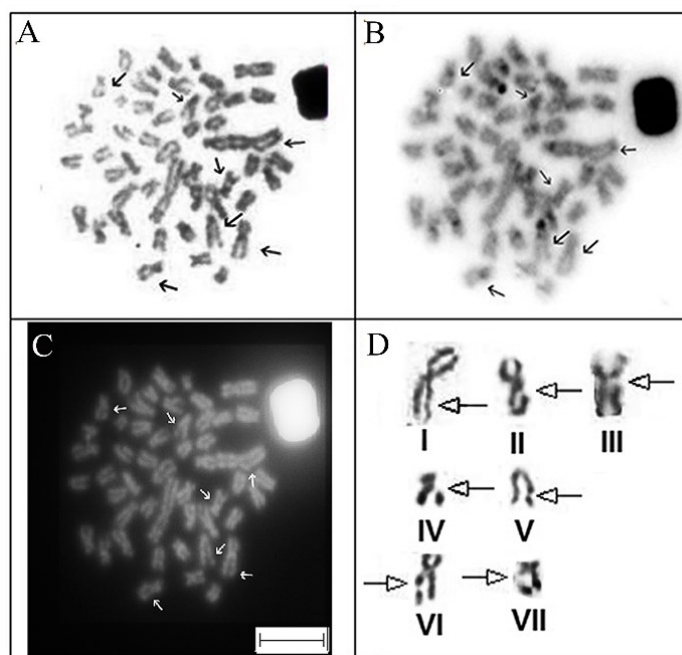
Figure 1. Metaphases of *Astyanax lacustris* (Lütken, 1875): A) Control group. (B-F) Groups after exposure to Dormex® solution; the arrows indicate chromosomal aberrations. B) Chromatid breaks and gaps (0.05 mL L⁻¹, 24 hours), Ag-NOR chromosome highlighted (arrowhead and box). C) Region of descondensation (0.05 mL L⁻¹, 48 hours). D) Acentric fragment (0.5 mL L⁻¹, 24 hours). E) Chromatid breaks and gaps (0.5 mL L⁻¹ for 48 hours). F) Chromatid breaks (0.5 mL L⁻¹ for 72 hours). Bar = 100 µm.

Some herbicides, such as those in the HRAC (Herbicide Resistance Action Committee) group, interfere with cell division, including the dinitroaniline, phosphoramidate, pyridine, benzamide, benzoic acid, carbamate, and arylaminopropionic acid classes of compounds (Beffa, Menne, & Köcher, 2019). These herbicides act through physiological different mechanisms, including the inhibition of the assembly or organization of microtubules, the prevention of the separation of the chromosomes during meiosis, and interference with the synthesis of new cell membranes or the cellulose component of the cell wall (Solomon et al., 2013; Beffa et al., 2019). Soltys et al. (2011), analyzed the cytotoxic effects of hydrogen cyanamide on the roots of the onion, *Allium cepa* L., and observed a number of alterations, such as a reduction in the number of mitotic cells (mitotic index), inhibition of the proliferation of the meristematic cells and the cell cycle, and modifications in the arrangement of the cytoskeleton. Given this, the reduction of the mitotic index observed in the kidney cells of *A. lacustris* in the present study can, likely be explained by the hydrogenated cyanamide affecting mitotic cell division through at least one of these mechanisms.

The types of aberrations found in the chromosome structure of the *A. lacustris* specimens included chromatid breaks, chromatid gaps, decondensation, and acentric fragments (Figure 1B-F; Figure 3D). These chromosomal aberrations were classified following Savage (2004). Chromosome or chromatid breaks are identified by a shifted fragment, which does not align with the rest of the chromatid, resulting in a discontinuity in the remainder of the chromosome, which is wider. Chromosome gaps are small, discolored regions that may appear in varying positions on the chromosome arm. Chromosome aberrations have been recorded in numerous fish species exposed to pesticides. Chromatid breaks and gaps, and acentric fragments have been observed in *Channa punctatus* exposed to the insecticide Dichlorvos® (Rishi & Grewal, 1995), in *Clarius batrachus* exposed to the carbamate fungicide Mancozeb® (Srivastava & Singh, 2013), and in *Cirrhinus mrigala* (Hamilton) exposed to Butachlor (Yadav et al., 2013).

Table 1. Mean \pm standard deviation of the mitotic index of kidney cells counts of *Astyanax lacustris* (Lütken, 1875) exposed to Dormex® (4,000 cells per group).

Experimental Groups (Concentrations)	Exposure time (hour)	(mean \pm standard deviation)
Control	24	2.10 \pm 0.47
	24	0.55 \pm 0.20*
	48	0.42 \pm 0.20*
0.05 mL L ⁻¹	72	0.22 \pm 0.14*
	24	0.42 \pm 0.20*
	48	0.45 \pm 0.06*
0.1 mL L ⁻¹	72	0.20 \pm 0.12*
	24	0.22 \pm 0.14*
0.5 mL L ⁻¹	48	0.37 \pm 0.16*
	72	0.45 \pm 0.06*

*Indicates significant difference in relation to the control ($p < 0.05$).**Figure 2.** Mitotic index of the kidney cells of the *Astyanax lacustris* (Lütken, 1875) specimens after treatment with Dormex®: A) 0.05; B) 0.1; and C) 0.5 mL L⁻¹. *Indicate significant difference in relation to the control group ($p < 0.05$).**Figure 3.** Sequential metaphases of *Astyanax lacustris* (Lütken, 1875) following exposure to Dormex® (0.05 mL L⁻¹ for 24 hours): A) Conventional Giemsa staining. B) C-banding. C) DAPI. D) Individualized chromosomes showing chromatid breaks in the long arms (I, II, III, IV, VI, VII) and a chromatid gap (V). Bar = 100 μ m.

The cytotoxicity of Dormex® in the kidney cells of *A. lacustris* was also assessed by chromosomal banding (Ag-NORs, DAPI staining, and C-banding), to detect specific regions corresponding to aberrations. Staining with silver nitrate (Ag-NOR) identified a homologous pair of nucleolar, which had a decondensed region (secondary constriction) in the short arm of a submetacentric chromosome (Figure 1B, arrowhead). The C-banding revealed a few heterochromatic blocks, distributed in the pericentromeric and telomeric regions of some chromosomes, including the nucleolar pair. However, most of the alterations involved the long arms of the metacentric, submetacentric, and acrocentric chromosomes (Figure 3D), and did not coincide with the

heterochromatic blocks. The chromatid breaks shown in Figure 3A were negative for DAPI staining, which indicates a lack of AT repeats (Figure 3C). The distribution of inter- and intra-chromosomal breakpoints does not appear to be random, and breaks tend to occur preferentially in active regions of the chromatin (Obe et al., 2002), as shown in the present study, where the break points do not coincide with heterochromatic regions. However, this pattern requires confirmation through a larger sample of C-banded metaphases in exposed specimens.

The cytogenetic data presented here characterize the genotoxic potential of Dormex® in *A. lacustris*. The fact that the number of metaphases with CAs did not vary significantly does not override the harmful effects of this herbicide in fish, even at low concentrations, and reinforces the need for caution in the application of this herbicide in areas close to aquatic environments.

Histological evaluation

The respiratory system is the principal interface between a fish and its aquatic environment, and is thus the first organ to be affected by pollutants dissolved in the water (Heath, 1995). The variation in the morphology of the gills of *A. lacustris* following exposure to Dormex® at different concentrations and exposure times are shown in Figure 4 and 5. In the control group, the morphology of the gills was preserved, with well-defined spaces developing between the secondary lamellae (Figure 4A). Exposure to Dormex® caused a significant increase in the extension of the tissue, resulting in lamellar fusion (Figure 4B) and hyperplasia (Figure 4C) of the gills in all the concentrations and exposure times, in comparison with the group control. Lamellar edemas (aneurysms) were also observed, albeit less frequently, in the gills of all the specimens exposed to Dormex® (Figure 4D).

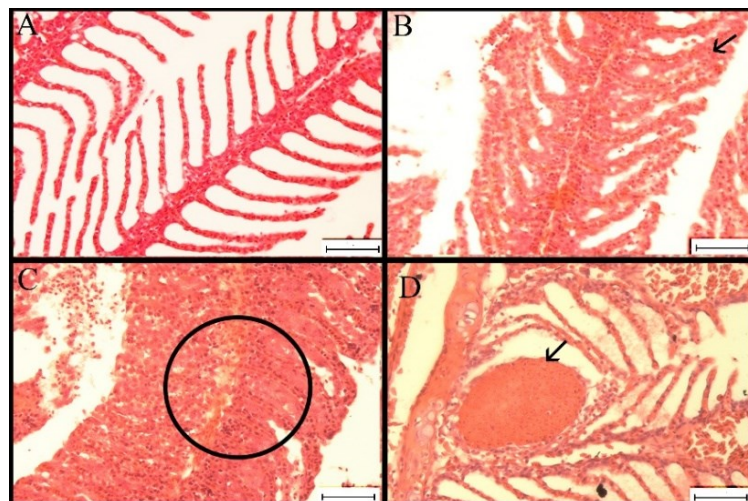


Figure 4. Photomicrographs of the gills of *Astyanax lacustris* (Lütken, 1875): A) Normal structure. B) Lamellar fusion (arrow). C) Epithelial hyperplasia (circled). D) Lamellar edema (arrow). HE (20X). Bar = 50 µm.

The histopathological effects of pesticides on fish have been studied widely, and include alterations to the gills, liver, blood vessels, and kidney (Castro, Silva, Freitas, & Carvalho-Neta, 2014; El-Sharaby et al., 2018; Velmurugan, Cengiz, Yolcu, Uğurlu, & Selvanayagam, 2020). In fish, the gills initially respond through hyperplasia, which results in increased cell and tissue function, caused by physiological changes (Takashima & Hibiya, 1995). Histological analyses of the gills, liver, skin, and brain of *Piaractus brachipomus* (Cuvier, 1818) exposed to different concentrations of the glyphosate-N (phosphonomethyl) glycine herbicide (Roundap®) revealed extensive anatomo-pathological alterations, included interlamellar hyperplasia, lamellar fusion, and edema in the gills which indicates that these organs are targets of the toxic effects of this herbicide (Ramírez-Duarte, Rondón-Barragán, & Eslava-Mocha, 2008).

Morphological damage to fish gills, such as epithelial hyperplasia, lamellar fusion and epithelial elevation, after exposure to pesticides, act as defense mechanisms, and generally cause a decrease in the respiratory surface, thereby inhibiting pesticide absorption and increasing the pesticide-blood diffusion distance (Velmurugan et al., 2020). The decrease in the surface area available for respiration also results in a loss of osmoregulatory mechanisms (Nogueira, Castro, Vieira, & Rigolin-Sá, 2011), and may ultimately result in death from anoxia (Rand & Petrocelli, 1985). This defense mechanism was probably triggered in the

A. lacustris individuals in response to exposure to the Dormex®. The analysis of the mean changes values (M.C.Vs) also indicates a gradual increase in the severity of the lesions (hyperplasia and lamellar fusion) in the *A. lacustris* specimens over time and among the different concentrations (Figure 5). However, animals exposed to Dormex® over 72 hours did not survive, due to the anoxic mechanism.

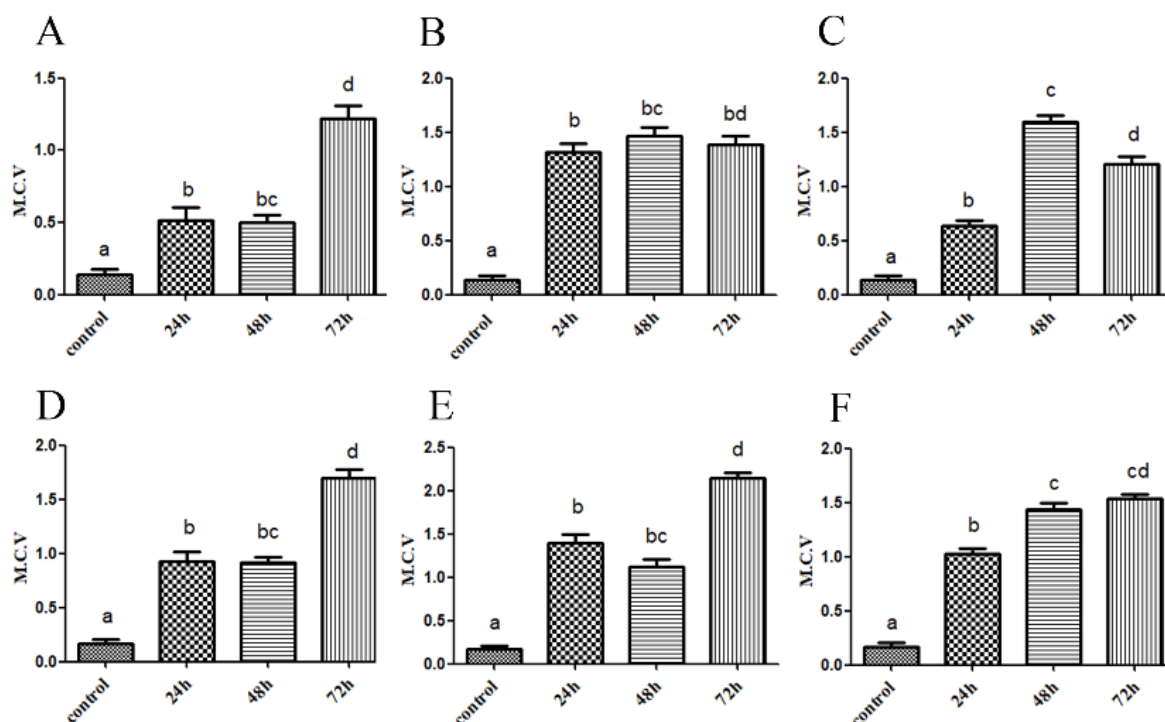


Figure 5. Mean Change Values (M.C.V.) in the gills of *Astyanax lacustris* (Lütken, 1875): Hyperplasia; A) 0.05; B) 0.1; C) 0.5 and Lamellar fusion; D) 0.05; E) 0.1; and F) 0.5 mL L⁻¹. ^{a,b,c,d}Indicates significant difference in relation to the control ($p < 0.05$).

The effects of aquatic contaminants have been evaluated in other *Astyanax* species. Specimens of *Astyanax altiparanae* Garutti & Britski, 2000 and *A. fasciatus* presented a range of morphological alterations of the gills, such as lamellar aneurysm, epithelial elevation, hyperplasia, and hypertrophy, in response to the poor water quality (Winkaler, Silva, Galindo, & Martinez, 2001). Virgens, Castro, and Cruz (2015), also showed histological changes in the gills of Nile tilapia (*Oreochromis niloticus*), exposed to Acephate, Diphenconazole, and Sulfluramide at concentrations typically used by farmers, and concluded that these agrochemicals impact the aquatic environment and induce lesions in the gills of *O. niloticus* that have negative impact on the respiratory physiology of these fish.

Conclusion

The present study provides the first evidence on the genotoxic and morphological effects of Dormex® on *A. lacustris* specimens, based on the analysis of cytogenetic and histological biomarkers. This integrated analyses proved highly effective for the understanding of the impact suffered by the fish at a cellular level when exposed *in vivo* to the herbicide Dormex®. These findings reinforce the need for special care and restrictions on the use of these herbicides in agricultural areas located near aquatic environments.

Acknowledgements

We thank the Brazilian Agency CAPES (Coordenação de Aperfeiçoamento de Pessoal de Nível Superior, Brazil) - Fundação Araucária for financial support and Dr. Weferson Júnio da Graça (Departamento de Biologia, Nupélia - Núcleo de Pesquisa em Limnologia, Icitologia e Aquicultura - UEM) for the identification of species.

References

Alavanja, M. C. R. (2009). Pesticides use and exposure extensive worldwide. *Environmental Health*, 24(4), 303-309. doi: 10.1515/REVEH.2009.24.4.303

- Beffa, R., Menne, H., & Köcher, H. (2019). Herbicide resistance action committee (HRAC): Herbicide classification, resistance evolution, survey, and resistance mitigation activities. In P. Jeschke, M. Witschel, & W. Krämer (Eds.), *Ulrich schirmer modern crop protection compounds* (3rd ed., p. 5-32). Weinheim, GE: Wiley Online Books.
- Behmer, O. A., Tolosa, E. M. C., & Freitas Neto, A. G. (1976). *Manual de técnicas para histologia normal e patológica*. São Paulo, SP: Edusp/Edart.
- Bertollo, L. A. C., Takahashi, C. S., & Moreira Filho, O. (1978). Cytotaxonomic considerations on *Hoplias lacerdae* (Pisces, Erythrinidae). *Brazilian Journal of Genetics*, 1, 103-120.
- Carvalho, F. P. (2006). Agriculture, pesticides, food security and food safety. *Environmental Science & Policy*, 9(7-8), 685-692. doi: 10.1016/j.envsci.2006.08.002
- Carvalho, F. P. (2017). Pesticides, environment, and food safety. *Food and Energy Security*, 6(2), 48-60. doi: 10.1002/fes3.108
- Castro, J. S., Silva, J. S., Freitas, L. C., & Carvalho-Neta, R. N. F. (2014). Biomarcadores histopatológicos na espécie *Hoplias malabaricus* (Pisces, Osteichthyes, Erythrinidae) em uma Unidade de Conservação de São Luís (MA). *Arquivo Brasileiro de Medicina Veterinária e Zootecnia*, 66(6), 1687-1694. doi: 10.1590/1678-7414
- Cavaş, T., & Könen, S. (2007). Detection of cytogenetic and DNA damage in peripheral erythrocytes of goldfish (*Carassius auratus*) exposed to a glyphosate formulation using the micronucleus test and the comet assay. *Mutagenesis*, 22(4), 263-268. doi: 10.1093/mutage/gem012
- Dane, H., & Şişman, T. (2017). A histopathological study on freshwater fish species chub (*Squalius cephalus*) in the Karasu River, Turkey. *Turkish Journal of Zoology*, 40(1), 1-11. doi: 10.3906/zoo-1509-21
- El-Sharaby, S. M. A., Abd-Elgaber, M., Tarabees, R., Khalil, R. H., Ali, M. N., & El-Ballal, S. (2018). Bacteriological and histopathological studies on vibrio species isolated from naturally infected freshwater fish in Delta Region, Egypt. *Advances in Animal and Veterinary Sciences*, 6(1), 17-26. doi: 10.17582/journal.aavs/2018/6.1.17.26
- Heath, A. G. (1995). *Water pollution and fish physiology* (2nd ed). Boca Raton, FL: CRC Press.
- Howell, W. M., & Black, D. A. (1980). Controlled silver-staining of nucleolus organizer regions with a protective colloidal developer: a 1-step method. *Experientia*, 36, 1014-1015. doi: 10.1007/BF01953855
- Inoue, L. A. K. A., & Moraes, G. (2007). Óleo de cravo: um anestésico alternativo para o manejo de peixes. *Embrapa Amazônia Ocidental*, 51, 1-22.
- Kienzler, A., Bony, S., & Devaux, A. (2013). DNA repair activity in fish and interest in ecotoxicology: A review. *Aquatic Toxicology*, 15(134-135), 47-56. doi: 10.1016/j.aquatox.2013.03.005
- Lins, J. A. P. N., Kirschnik, P. G., Queiroz, V. S., & Cirio, S. M. (2010). Uso de peixes como biomarcadores para monitoramento ambiental aquático. *Revista Acadêmica Ciências Agrárias e Ambiente*, 8(4), 469-484. doi: 10.7213/cienciaanimal.v8i4.11018
- Lucena, C. A. S., & Soares, H. G. (2016). Review of species of the *Astyanax bimaculatus* “caudal peduncle spot” subgroup sensu Garutti & Langeani (Characiformes, Characidae) from the rio La Plata and rio São Francisco drainages and coastal systems of southern Brazil and Uruguay. *Zootaxa*, 4072(1), 101-125. doi: 10.11646/zootaxa.4072.1.5
- Lui, R. L., Blanco, D. R., Margarido, V. P., & Moreira Filho, O. (2009). First description of B chromosomes in the family Auchenipteridae, *Parauchenipterus galeatus* (Siluriformes) of the São Francisco River basin (MG, Brazil). *Micron*, 40(5-6), 552-559. doi: 10.1016/j.micron.2009.03.004
- Lütken, C. F. (1875). Peixes do rio das Velhas: uma contribuição para a ictiologia do Brasil. In C. B. M. Alves, & P. S. Pompeu (Org.), *Peixes do rio das Velhas: passado e presente* (p. 23-164). Belo Horizonte, MG: SEGRAC.
- Mallatt, J. M. (1985). Fish gill structural changes induced by toxicants and other irritants: a statistical review. *Canadian Journal of Fisheries and Aquatic Sciences*, 42(4), 630-648. doi: 10.1139/f85-083
- Mohanty, G., Mohanty, J., Nayak, A. K., Mohanty, S., & Dutta, S. K. (2011). Application of comet assay in the study of DNA damage and recovery in rohu (*Labeo rohita*) fingerlings after an exposure to phorate, an organophosphate pesticide. *Ecotoxicology*, 20(1), 283-292. doi: 10.1007/s10646-010-0580-2
- Nicolopoulou-Stamati, P., Maipas, S., Kotampasi, C., Stamatis, P., & Hens, L. (2016). Chemical pesticides and human health: The urgent need for a new concept in agriculture. *Frontiers in Public Health*, 4, 148. doi: 10.3389/fpubh.2016.00148

- Nogueira, D. J., Castro, S. C., Vieira, R. C. A., & Rigolin-Sá, O. (2011). Use of the gills of *Pimelodus maculatus* (Lacépède, 1803) (Siluriformes, Pimelodidae) as a biomarker of pollution in the reservoir of UHE Marechal Mascarenhas de Moraes, Minas Gerais, Brazil. *Biotemas*, 24(3), 51-58. doi: 10.5007/2175-7925.2011v24n3p51
- Obe, G., Pfeiffer, P., Savage, J. R. K., Johannes, C., Goedecke, W., Jeppesen, P., Drets, M. E. (2002). Chromosomal aberrations: formation, identification and distribution. *Mutation Research*, 504(1-2), 17-36. doi: 10.1016/s0027-5107(02)00076-3
- Pignatti, W. A., Lima, F. A. N. S., Lara, S. S., Correa, M. L. M., Barbosa, J. R., Leão, L. H. C., & Pignatti, M. G. (2017). Spatial distribution of pesticide use in Brazil: a strategy for health surveillance. *Ciência & Saúde Coletiva*, 22(10), 3281-3293. doi: 10.1590/1413-812320172210.17742017
- Ramírez-Duarte, W. F., Rondón-Barragán, I. S., & Eslava-Mocha, P. R. (2008). Acute toxicity and histopathological alterations of Roundup® herbicide on “cachama blanca” (*Piaractus brachypomus*). *Pesquisa Veterinária Brasileira*, 28(11), 547-554. doi: 10.1590/S0100-736X2008001100002
- Rand, G. M., & Petrocelli, S. R. (1985). Fundamentals of aquatic toxicology: methods and applications. In G. M. Rand & S. R. Petrocelli (Eds.), *Fundamentals of aquatic toxicology: methods and applications* (p. 1-28). Lansing, MI: Hemisphere.
- Rašković, B., Jarić, I., Koko, V., Spasić, M., Dulić, Z., Marković, Z., & Poleksić, V. (2013). Histopathological indicators: a useful fish health monitoring tool in common carp (*Cyprinus carpio* Linnaeus, 1758) culture. *Central European Journal of Biology*, 8(10), 975-985. doi: 10.2478/s11535-013-0220-y
- Rishi, K. K., & Grewal, S. (1995). Chromosome aberration test for the insecticide, dichlorvos, on fish chromosomes. *Mutation Research*, 344(1-2), 1-4. doi: 10.1016/0165-1218(95)90032-2
- Samanta, P., Kumari, P., Pal, S., Mukherjee, A. K., & Ghosh, A. R. (2018). Histopathological and ultrastructural alterations in some organs of *Oreochromis niloticus* exposed to Glyphosate-based herbicide, excel mera 71. *Journal of Microscopy and Ultrastructure*, 6(1), 35-43. doi: 10.4103/jmau.jmau_8_18
- Savage, J. R. K. (2004). On the nature of visible chromosomal gaps and breaks. *Cytogenetic and Genome Research*, 104(1-4), 46-55. doi: 10.1159/000077465
- Saxena, K. K., & Chaudhari, R. (2010). Study of chromosomal abnormalities in *Channa punctatus* exposed to fenvalerate. *Journal of Applied and Natural Science*, 2(1), 70-73. doi: 10.31018/jans.v2i1.99
- Schwaiger, J., Wanke, R., Adam, S., Pawert, M., Honnen, W., & Triebkorn, R. (1997). The use of histopathological indicators to evaluate contaminant-related stress in fish. *Journal of Aquatic Ecosystem Stress and Recovery*, 6(1), 75-86. doi: 10.1023/A:1008212000208
- Schweizer, D. (1980). Simultaneous fluorescent staining of R bands and specific heterochromatic regions (DA-DAPI bands) in human chromosomes. *Cytogenetics and Cell Genetics*, 27(2-3), 190-193. doi: 10.1159/000131482
- Segantini, D. M., Leonel, S., Ripardo, A. K. S., Tecchio, M. A., & Souza, M. E. (2015). Breaking dormancy of “tupy” blackberry in subtropical conditions. *American Journal of Plant Sciences*, 6(11), 1760-1767. doi: 10.4236/ajps.2015.611176
- Silva, D. A., Pessoa, E. K. R., Costa, S. A. G. L., Chellappa, N. T., & Chellappa, S. (2012). Ecologia reprodutiva de *Astyanax lacustris* (Osteichthyes: Characidae) na Lagoa do Piató, Assú, Rio Grande do Norte, Brasil. *Biota Amazônica*, 2(2), 54-61. doi: 10.18561/2179-5746
- Solomon, K. R., Dalhoff, K., Volz, D., & Kraak, G. V. D. (2013). Effects of herbicides on fish. *Fish Physiology*, 33, 369-409. doi: 10.1016/B978-0-12-398254-4.00007-8
- Soltys, D., Rudzinska-Langwald, A., Kurek, W., Gniazdowska, A., Sliwinska, E., & Bogatek, R. (2011). Cyanamide mode of action during inhibition of onion (*Allium cepa* L.) root growth involves disturbances in cell division and cytoskeleton formation. *Planta*, 234(3), 609-621. doi: 10.1007/s00425-011-1429-5
- Srivastava, P., & Singh, A. (2013). Induction of chromosomal aberrations by Carbamate fungicide in fish *Clarius batrachus* (Asian Catfish). *Scholarly Journal of Agricultural Science*, 3(11), 487-491.
- Sumner, A. T. (1972). A simple technique for demonstrating centromeric heterochromatin. *Experimental Cell Research*, 75(1), 304-306. doi: 10.1016/0014-4827(72)90558-7
- Tabassum, H., Dawood, A. Q., Sharma, P., Khan, J., Raisuddin, S., & Parvez, S. (2016). Multi-organ toxicological impact of fungicide propiconazole on biochemical and histological profile of freshwater fish *Channa punctata* Bloch. *Ecological Indicators*, 63, 359-365. doi: 10.1016/j.ecolind.2015.11.052

- Takashima, F., & Hibiya, T. (1995). *An atlas of fish histology: normal and pathological features*. Sacramento, CA: Gustav Fischer Verlag.
- Umar-Tsafe, N., Mohamed-Said, M. S., Rosli, R., Din, L. B., & Lai, L. C. (2004). Genotoxicity of goniothalamine in CHO cell line. *Mutation Research*, 562(1-2), 91-102. doi: 10.1016/j.mrgentox.2004.05.011
- Velmurugan, B., Cengiz, E. I., Yolcu, M., Uğurlu, P., & Selvanayagam, M. (2020). Cytological and histological effects of pesticide chlorpyrifos in the gills of *Anabas testudineus*. *Drug and Chemical Toxicology*, 43(4), 409-414. doi: 10.1080/01480545.2018.1497052
- Virgens, A. C., Castro, R. L., & Cruz, Z. M. A. (2015). Alterações histológicas em brânquias de *Oreochromis niloticus* (Tilapia-do-Nilo) expostas a Acefato, Difenconazol e Sulfluramida. *Natureza Online*, 13(1), 26-31.
- Winkler, E. U., Silva, A. G., Galindo, H. C., & Martinez, C. B. R. (2001). Biomarcadores histológicos e fisiológicos para o monitoramento da saúde de peixes de rios de Londrina, Estado do Paraná. *Acta Scientiarum. Biological Science*, 23(2), 507-514. doi: 10.4025/actasciobiolsci.v23i0.2708
- Yadav, A. S., Bhatnagar, A., & Kaur, M. (2013). Aberrations in the chromosomes of *Cirrhinus mrigala* (Hamilton) upon Exposure to Butachlor. *Iranian Journal of Toxicology*, 7(21), 858-865.