

# Ontogeny of the cranial bones of the giant amazon river turtle *Podocnemis expansa* Schweigger, 1812 (Testudines, Podocnemididae)

Lucélia Gonçalves Vieira\*, André Luiz Quagliatto Santos and Fabiano Campos Lima

Laboratório de Pesquisas em Animais Silvestres, Universidade Federal de Uberlândia, Av. João Naves De Avila, 2121, 38408-100, Uberlândia, Minas Gerais, Brazil. \*Author for correspondence. E-mail: luceliabio@yahoo.com.br

**ABSTRACT.** In order to determine the normal stages of formation in the sequence of ossification of the cranium of *Podocnemis expansa* in its various stages of development, embryos were collected starting on the 18<sup>th</sup> day of natural incubation and were subjected to bone diaphanization and staining. In the neurocranium, the basisphenoid and basioccipital bones present ossification centers in stage 19, the supraoccipital and opisthotic in stage 20, the exoccipital in stage 21, and lastly the prooptic in stage 24. Dermatocranium: the squamosal, pterygoid and maxilla are the first elements to begin the ossification process, which occurs in stage 16. However, ossification centers begin to appear in stage 17 in most of these bone elements, i.e., the frontal, jugal, postorbital, parietal, premaxilla and prefrontal, followed by the palatine and quadratojugal in stage 19 and lastly by the vomer in stage 25. The quadrate bone of the splanchnocranium ossifies in stage 23. The mandible and hyoid apparatus, the dentary, coronoid and supra-angular, show ossification centers in stage 16 and the branchial horn I in stage 17. The sequence and synchronization of ossification in *P. expansa* show similarities as well as differences when compared with other species of Testudines.

**Key words:** reptiles, Podocnemididae, alizarin, ossification.

**RESUMO.** Ontogenia dos ossos do crânio em tartaruga-da-amazônia *Podocnemis expansa* Schweigger, 1812 (Testudines, Podocnemididae). Com o propósito de estabelecer etapas normais de formação da sequência de ossificação do crânio em *Podocnemis expansa*, nos diferentes estágios de desenvolvimento, coletaram-se embriões a partir do 18<sup>o</sup> dia de incubação natural, os quais foram submetidos à técnica de diafanização e coloração dos ossos. No neurocrânio, no estágio 19, o basisfenoide e o basioccipital apresentam centro de ossificação; no estágio 20, o supraoccipital e o opistótico; no estágio 21, o exoccipital; somente no estágio 24, o proótico. Dermatocrânio: o esquamosal, o pterigoide e a maxila são os primeiros elementos a iniciar o processo de ossificação, que ocorre no estágio 16. Mas a maioria desses elementos ósseos apresenta centros de ossificação no estágio 17, são eles: frontal, jugal, pós-orbital, parietal, pré-maxila, pré-frontal, seguido do palatino e quadratojugal no estágio 19 e, por último, o vômer no estágio 25. O osso quadrado do esplanocnocrânio, no estágio 23. Ossificação da mandíbula e aparelho hioide: tanto o dentário, coronoide e o supra-angular apresentam centros de ossificação no estágio 16; o corpo branquial I, no estágio 17. A sequência e a sincronização da ossificação em *P. expansa* exibem similaridades, bem como diferenças, quando comparada com outras espécies de Testudines.

**Palavras-chave:** répteis, Podocnemididae, alizarina, ossificação.

## Introduction

The skeleton of vertebrates is composed of cartilage and bone and is the product of cells from three distinct embryonic lines. The cranium is composed of neural crest cells (OLSEN et al., 2000; CLARK et al., 2001). The cells of this line migrate to where the skeletal elements will develop, forming characteristic condensations of mesenchymal cells and differentiating into osteoblasts or chondrocytes. In certain regions of the cranium, differentiation

into osteoblasts directly produces membrane bones, while in others differentiation into chondrocytes produces cartilage models of future bones. These cartilage models are later replaced by bone through endochondral ossification (OLSEN et al., 2000).

In the bone elements of the cranium, several genes have been identified as regulators of differentiation and migration of neural crest cells (BRONNER-FRASER, 1994). This contributes to a variety of tissues, including cartilage and bone. This

process is characterized by temporal changes in patterns determined by a genic expression (NAH et al., 2000).

According to Hildebrand and Goslow (2006), the cranial skeleton is extremely important for phylogeny and systematics at all levels, but it is particularly notable for the study of taxa, reptile subclasses and the transition from reptile to mammal. A considerable variation occurred in the temporal region of reptiles during evolution. Reptiles with primitive torsos, represented by cotylosauria of the Carboniferous and Permian periods, did not have a special temporal opening in the skull. Among extant reptiles, the solid condition of the skull without openings – anapsid, is exclusive to turtles.

Several researchers have studied the sequence of ossification of the bone elements of the skull of Testudines, including the species *Chelydra serpentina* (RIEPEL, 1993), *Apalone spinifera* (SHEIL, 2003) and *Macrochelys temminckii* (SHEIL, 2005). However, those studies did not involve *Podocnemis expansa*. This species, popularly known as the giant Amazon river turtle, is a fluvial Testudines of the family Podocnemididae found in the Amazon river and in almost all its tributaries. It is a large species whose largest specimens reach lengths of up to more than 90 centimeters (GASPAR et al., 2001; HIRANO et al., 2009).

Knowledge of biological criteria for the sequence of bone formation at sites and predictable times is extremely important for activities of conservation, for preservation, as bioindicators, for production, and also for scientific research (BELL et al., 2006; GRAY et al., 1996; MADER et al., 2006). The objective of the present research is to describe the sequence of formation of the bone elements that make up the skull of *P. expansa* in the different stages of prenatal development.

## Material and methods

Sixty-two embryos of *Podocnemis expansa* (Testudines, Podocnemididae) were collected during the spawning period of 2005 and 2006, in the area of reproduction protected by the RAN – Center for Reptile and Amphibian Conservation and Management on the beaches of the Araguaia river in Goiás State, Brazil, in the region called Remansão (13° 20' 38.7" S and 50° 38' 05.7" W), under permit number 117/2005-IBAMA/RAN.

Egg specimens were collected randomly up to the moment of hatching from randomly chosen nests. This study examined embryos from stages 16 to 25. The stages of development of the embryos were named according to the external morphological

criteria proposed by Danni et al. (1990).

All the embryos were removed from the eggs by cutting the shells with surgical scissors, separating them from the vitellus and the membranous sacs. The specimens were subjected to diaphanization by KOH and staining of bones with alizarin red S and of cartilage with alcian blue, according to the method of Davis and Gore (1936) and Dingerkus and Uhler's (1977) modified method, at the Wild Animal Research Laboratory (LAPAS) of the Federal University of Uberlândia (UFU) Faculty of Veterinary Medicine.

Anatomical particularities of the bones of the skull of adult *P. expansa* were recorded as necessary elements for an understanding of the ontogenetic phenomena.

The presence of ossification centers, as well as the different stages of development of the bone elements that make up the cranium (Figures 3 and 4), were analyzed in a stereoscopic microscope (SZX 12, Olympus) coupled to a camera for capturing images (DP10, Olympus) and a digital camera (fe100, Olympus 6.0).

## Results

### Osteology of the cranium of adult *Podocnemis expansa*

#### Neurocranium

- Basisphenoid (Bas): articulated rostrally with the caudal edge of the pterygoid bone and caudally with the rostral edge of the basioccipital (Figure 1C).

- Supraoccipital (Su): is an unpaired bone, medial, which forms the caudodorsal surface of the calvaria of the skull. It supports the median supraoccipital crest that extends caudally beyond the paraoccipital process of the squamosal and opisthotic bones. The lateral edge of the supraoccipital projects ventrolaterally, forming the caudomedial surface of the temporal fossa. Laterally, the supraoccipital articulates with the prooptic and the opisthotic and dorsally with the medial edge of the parietal bone. The supraoccipital forms the dorsal edge of the foramen magnum (Figure 1D).

- Basioccipital (Ba): appears as a single medial element. It supports a prominent ventromedial process that forms the third ventral occipital condyle; the dorsal edge of the basioccipital separates the exoccipital medially and forms the ventral edge of the foramen magnum. Rostrally it articulates with the caudal edge of the basisphenoid. The dorsal surface of the basioccipital articulates with the ventrolateral edge of the exoccipital, and forms the caudal floor of the cranial cavity (Figure 1C).

- Opisthotic (Op): the rostral edge of each

opisthotic is irregular and articulates with the caudal edge of the prooptic. The medial edge of each articulates with the lateral edge of the supraoccipital. Laterally, each opisthotic is joined widely with the medial edge of the quadrate of the squamosal (Figure 1D).

- Exoccipital (Ex): are paired bones that form the ventrolateral edge of the foramen magnum, contributing to the dorsolateral formation of the occipital condyle. Each exoccipital articulates with the caudolateral edge of the supraoccipital and laterally with the caudomedial edge of the opisthotic, as well as ventrally and medially with the basioccipital (Figure 1D).

- Prooptic (Pr): each prooptic is slightly concave dorsally and forms the rostral floor of the temporal fossa. Medially, each prooptic articulates with the lateral edge of the parietal and with the rostromedial edge of the supraoccipital. Caudally it articulates with the rostral edge of the opisthotic and laterally with the dorsomedial edge of the quadrate (Figure 1D).

#### Dermatocranium

- Frontal (Fr): the frontal bones are joined medially along their entire length, articulating rostrally with the prefrontal bones, caudally with the parietal bones and caudolaterally with the postorbital bones. The rostromedial edge of each frontal bone is slightly concave and forms the dorsomedial rim of the orbit (Figures 1A and B).

- Maxilla (Ma): has a grinding surface extending along the entire length of the ventral region of each element. It has numerous small foramina located on the facial surface and grinding surface. Each maxilla is joined to the caudolateral edge of the premaxilla. The prefrontal process of each maxilla is triangular, forming the rostroventral rim of the orbit and articulating with the lateral edge of the prefrontal. Caudally, each maxilla articulates widely with the rostral edge of the jugal bone, and caudoventrally with the rostral edge of the palatine (Figures 1A and B).

- Jugal (Ju): caudally, the jugal articulates with the rostral rim of the quadratojugal. The rostral rim of each jugal articulates with the caudodorsal rim of the maxilla, forming the caudoventral rim of the orbit. Inside the orbital fossa, the jugal is slightly concave and articulates with the mediocaudal surface of the maxilla. The dorsal edge of the jugal is joined to the postorbital and parietal. The short caudomedial process of the jugal articulates with the rostromedial surface of the palatine and of the pterygoid (Figures 1A and B).

- Postorbital (Po): this is a small paired bone. Each postorbital articulates laterally with the dorsal

edge of the jugal, medially with the caudolateral edge of the frontal, and caudally with the rostromedial edge of the parietal. The postorbital articulates with the pterygoid and with the palatine in a ventrocaudal expansion. It forms the laterodorsal rim of the orbit and the caudodorsal wall of the orbital fossa (Figures 1A and B).

- Parietal (Pa): a wide pair of bones that form a large part of the roof of the skull. They are joined medially along their entire length. The parietal articulates with the supraoccipital caudally, with the frontal rostromedially, and with the postorbital and the jugal rostromedially. Ventrolaterally, the parietal articulates with the prooptic and laterally with the medial edge of the quadratojugal (Figures 1A and B).

- Squamosal (Sq): viewed dorsally, the squamosal forms a joint with the lateral edge of the opisthotic. When viewed laterally, the rostral edge of each squamosal articulates with the quadratojugal and with the caudomedial edge of the quadrate bone (Figures 1A and B).

- Palatine (Pal): is a paired bone whose rostral halves are joined medially. The caudal halves are separated medially by the vomer. Each palatine articulates with the caudoventral edge of the maxilla, with the rostral edge of the pterygoid caudally, and with the jugal laterally (Figure 1C). In the orbital fossa, the dorsal process of the palatine articulates with the postorbital.

- Pterygoid (Pt): a wide bone with transverse processes. Rostrally it articulates with the caudal edge of the palatine and caudally with the basisphenoid. Rostrolaterally, each pterygoid supports a rostral branch that projects dorsally and articulates with the jugal and with a small part of the caudal rim of the postorbital (Figure 1C).

- Premaxilla (Prm): are two small bones fused to each other medially. They articulate laterally with the maxilla and form the rostral edge of the snout. The fused premaxilla support part of the grinding surface of each maxilla (Figure 1C).

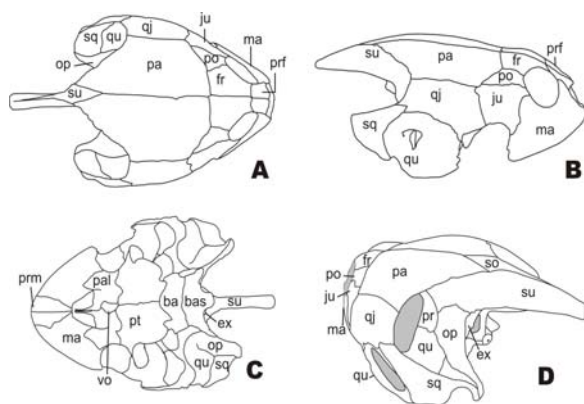
- Prefrontal (Prf): these bones are joined medially along their entire length, forming the roof of the nasal cavity. The caudal, rostral and lateral rims are irregular. The prefrontal articulates caudally with the frontal and laterally with the maxilla. Laterally it forms the rostromedial rim of the orbit (Figures 1A and B).

- Quadratojugal (Qj): viewed dorsally, the quadratojugal forms the dorsolateral wall of the temporal fossa. Viewed laterally, the caudal edge of the quadratojugal articulates with the rostral edge of the squamosal, rostrally with the caudal edge of the jugal and ventrally with the quadrate (Figures 1A and B).

- Vomer (Vo): is located medially and separates the palatine caudally. It articulates caudally with the pterygoid (Figure 1C).

### Splanchnocranium

- Quadrate (Qu): ventrally, each quadrate bone supports a mandibular condyle, which articulates with the mandible. Viewed laterally, the quadrate bone forms a large part of the wall of the tympanum cavity. The rostromedial portion of the quadrate proceeds towards the prooptic, joining it. The caudal edge articulates with the rostral edge of the squamosal and caudomedially with the opisthotic. Medially, each quadrate articulates widely with the caudal branch of the pterygoid. In lateral view, the dorsal edge of the quadrate bone articulates with the lateral edge of the quadratojugal (Figures 1A and B).



**Figure 1.** Schematic drawing of the skull of *Podocnemis expansa*. (A) dorsal view; (B) lateral view; (C) ventral view; (D) laterocaudal view. Pa, parietal; Fr, frontal; Prf, prefrontal; Po, postorbital; Ju, jugal; Ma, maxilla; Qj, quadratojugal; Su, supraoccipital; Qu, quadrate; Sq, squamosal; Prm, premaxilla; Ba, basioccipital; Bas, basisphenoid; Pt, pterygoid; Pal, palatine; Vo, vomer; Op, opisthotic; Pr, prooptic; Ex, exoccipital.

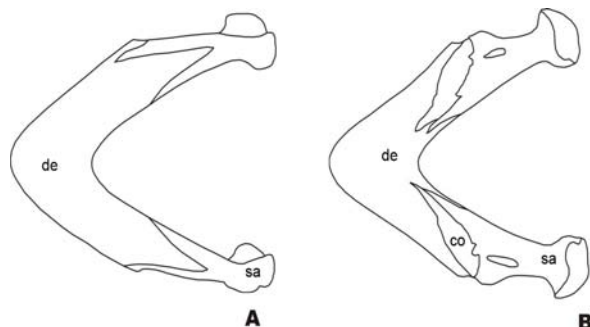
### Mandible

In Testudines, the dorsal view of the mandible is normally V-shaped. The two halves of the mandible are fused, indicating no limit between them, and comprise: (1) the coronoid, (2) the dentary, and (3) the supra-angular.

Coronoid (Co): a bone element situated dorsally between the dentary rostrally and the supra-angular caudally. Medially, its ventral edge contributes to form the sulcus meckelii (Figures 2A and B).

- Dentary (De): forms the major part of the rostral, lateral and ventral surfaces of the mandible. The caudolateral edge of the dentary is irregular and invests laterally in the direction of the ventral rims of the coronoid and the supra-angular. The labial edge extends along the entire lateral region of the dentary and is perforated by numerous small

foramina. The dorsal edge of the lingual surface of the dentary is prominent and the sulcus meckelii extends along the entire length of its medial face (Figures 2A and B).



**Figure 2.** Schematic drawing of the mandible of *Podocnemis expansa*. (A) ventral view of the mandible; (B) dorsal view of the mandible. De, dentary; Co, coronoid; Sa, supra-angular.

- Supra-angular (Sa): is a narrow bone element forming part of the caudal third of the mandible. The supra-angular forms the medial wall of the area articularis mandibularis. Viewed laterally, the rostradorsal edge of the supra-angular articulates with the caudolateral edge of the coronoid and the rostrrolateral edge invests the dentary (Figures 2A and B).

### Hyoid apparatus

The hyoid body, lingual process, branchial horn I and branchial horn II form the hyoid apparatus of *P. expansa*. The branchial horn I is curved dorsomedially and is longer than branchial horn II, which is the only element of the hyoid apparatus that ossifies.

### Sequence of ossification of the bone elements of the skull of *P. expansa*

#### Neurocranium

The basisphenoid and the basioccipital begin the ossification process in stage 19, followed by the supraoccipital and the opisthotic in stage 20 and the exoccipital in stage 21 (Figure 3E). The prooptic is the last element of the neurocranium to present an ossification center, which occurs only in stage 24.

In stage 22, the basioccipital and the basisphenoid are oval-shaped. The basisphenoid proceeds in the direction of the caudal edge of the pterygoid, reaching it only in stage 23 and proceeding in the direction of the cranial edge of the basioccipital. Still in this stage, the supraoccipital dorsally approaches the caudal edge of the parietals (Figure 3).

The supraoccipital approaches the exoccipital, the opisthotic and the prooptic in stage 25. The

opisthotic approaches the exoccipital and the squamosal and proceeds in the direction of the prooptic, also in this stage.

### Dermatocranium

The squamosal, pterygoid and maxilla are the first elements of the dermatocranium to begin ossification, which occurs in stage 16 (Figure 3B). However, the majority of these bone elements present ossification centers in stage 17, i.e., the frontal, jugal, postorbital, parietal, premaxilla, and prefrontal (Figure 3), followed by the palatine and quadratojugal in stage 19, and lastly by the vomer in stage 25 (Figure 3).

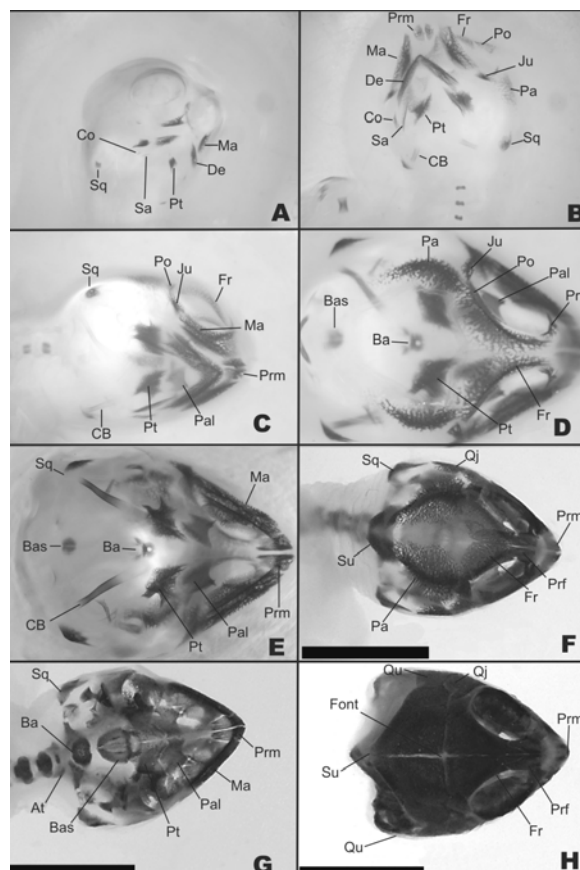
In stage 22 the frontal proceeds in the direction of the rostral edge of the parietal, medially approaching its contralateral opposite and the caudal edge of the prefrontal. The maxilla occupies most of the ventral edge of the orbit. The pterygoid already approaches the palatine rostrally and proceeds caudally in the direction of the basisphenoid. The palatine proceeds in the rostromedial direction, remaining close to the maxilla.

The frontal approaches the parietal, contributing to the formation of the fontanelle in stage 23. The maxilla approaches the rostrolateral edge of the palatine and, viewed laterally, also approaches the prefrontal. The jugal approaches the caudal edge of the maxilla, the lateral edge of the postorbital and the rostral edge of the parietal, proceeding in the direction of the quadratojugal. The postorbital, in turn, approaches the caudolateral edge of the frontal and the rostral edge of the parietal. The two parts of the parietals proceed in the medial direction to posterior fusion, approaching the quadratojugal laterally and the supraoccipital caudally. Still in stage 23, the squamosal proceeds in the direction of the quadratojugal while the pterygoid approaches the caudal edge of the basisphenoid (Figure 3F).

In stage 25, the frontal approaches the prefrontal, while the jugal approaches the postorbital, maxilla, quadratojugal and the parietal. The squamosal approaches the quadratojugal, quadrate and opisthotic. The right and left portions of the pterygoid, premaxilla and palatine approach each other medially in posterior fusion. The vomer is the last to present an ossification center.

### Splanchnocranium

In stage 23, the quadrate bone already presents an ossification center, proceeding in the direction of the opisthotic, squamosal and quadratojugal. In stage 24, the quadrate approaches the opisthotic (Figure 3H).

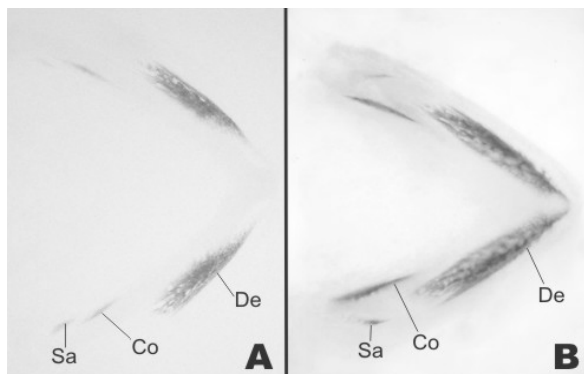


**Figure 3.** Photographs of the skull of *Podocnemis expansa*. (A) ventral view, stage 16; (B) ventral view, beginning of stage 17; (C) ventral view, end of stage 17; (D) dorsal view, stage 19; (E) ventral view, stage 19; (F) ventral view, stage 23; (G) dorsal view, stage 23; (H) dorsal view, stage 24. Pa, parietal; Fr, frontal; Prf, prefrontal; Po, postorbital; Ju, jugal; Ma, maxilla; Qj, quadratojugal; Su, supraoccipital; Qu, quadrate; Sq, squamosal; Prm, premaxilla; Ba, basioccipital; Bas, basisphenoid; Pt, pterygoid; Pal, palatine; Sa, supra-angular; De, dentary; Co, coronoid; At, atlanto-occipital articulation; Font, fontanelle; CB, branchial horn.

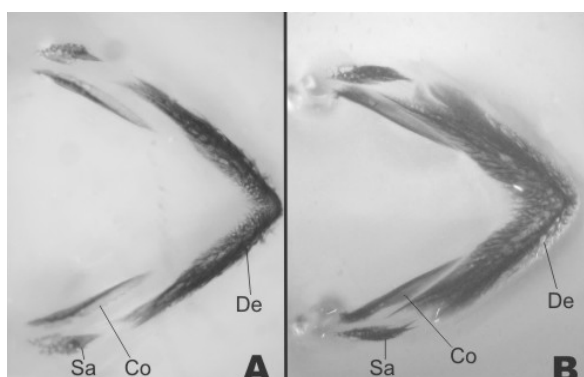
### Mandible and hyoid apparatus

The dentary, coronoid and supra-angular present ossification centers in stage 16, with greater dye retention in the dentary, indicating that this element is the first to present an ossification center (Figures 3A, B and 4A). The dentary approaches its opposite medially in stage 19 and begins to show numerous small foramina, while the supra-angular proceeds in the direction of the caudal edge of the coronoid. In stage 20, the dentary approaches the rostral edge of the coronoid and its caudal third invests in the rostral edge of the supra-angular (Figures 4B, 5A and B).

The branchial horn I of the hyoid apparatus begins to ossify at the end of stage 17. In stage 19, it proceeds in the direction of the caudal part of the hyoid body (Figures 3B, D and E).



**Figure 4.** Photographs of mandibles of *Podocnemis expansa*. (A) stage 16; (B) stage 17. De, dentary; Co, coronoid; Sa, supra-angular.



**Figure 5.** Photographs of mandibles of *Podocnemis expansa*. (A) stage 19; (B) stage 20. De, dentary; Co, coronoid; Sa, supra-angular.

## Discussion

### Neurocranium

In *Apalone spinifera*, the elements of the neurocranium ossify between stages 19 and 23 (SHEIL, 2003), in *Macrochelys temminckii* between stages 21 and 24 (SHEIL, 2005), and in *Chelydra serpentina* (RIEPPPEL, 1993; SHEIL; GREENBAUM, 2005) between stages 21 and 23, indicating that this is the period of longest duration in *Podocnemis expansa*, since it takes place between stages 19 and 24.

The sequence of formation of the bone elements of the neurocranium differs significantly among *C. serpentina*, *A. spinifera*, *M. temminckii* and *P. expansa*.

In *Podocnemis expansa*, the basisphenoid and the basioccipital are the first elements of the neurocranium to ossify. This is followed by the supraoccipital and the opisthotic, then the exoccipital, and lastly the prooptic. Rieppel (1993) reported that in *C. serpentina* the sequence of ossification of these elements occurs in the following order: the basisphenoid, followed by the exoccipital, basioccipital, supraoccipital, and prooptic, and lastly by the opisthotic. Still with

respect to *C. serpentina*, according to Sheil and Greenbaum (2005), ossification of the exoccipital slightly precedes that of the basisphenoid, and the supraoccipital ossifies before the prooptic, which in turn precedes ossification of the basioccipital.

In the species *M. temminckii* (SHEIL, 2005), the basisphenoid, exoccipital and prooptic are the first to present ossification centers, followed by the basioccipital, the supraoccipital and lastly the opisthotic. Sheil (2003) reports that in *A. spinifera*, the exoccipital and the basioccipital are the first to present ossification centers, followed by the basisphenoid and prooptic, then the opisthotic, and lastly the supraoccipital.

### Dermatocranium

Sheil and Greenbaum (2005) suggest that the bones of the dermatocranium were grouped into elements of the palatum (pterygoid, vomer and palatine), maxillary arch (premaxilla, maxilla, jugal, quadratojugal and squamosal) and the roof of the cranium (prefrontal, postorbital, frontal and parietal).

In *C. serpentina* (RIEPPPEL, 1993), the pterygoid, vomer and palatine ossify between stages 18 and 20. The exact order of ossification is: pterygoid > palatine = vomer. This sequence suggests that these palatal elements show a tendency to ossify caudorostrally. The same order of ossification of these elements has been observed in *C. serpentina*, but in different lengths of time, since these elements ossify earlier (SHEIL; GREENBAUM, 2005). However, in *A. spinifera*, Sheil (2003) observed basically the same order of ossification of these elements, with the pterygoid and the palatine presenting ossification centers in the same stage, as follows: pterygoid = palatine > vomer. Sheil (2005) reports that in *M. temminckii*, the pterygoid, palatine and vomer present ossification centers in stage 18, with the pterygoid more advanced, indicated by the greater retention of alizarin dye. A similar event occurs in these palatal bones in *P. expansa* and in *A. spinifera*, although it differs chronologically.

In *C. serpentina*, Rieppel (1993) observed that elements of the maxillary arch ossify between stages 18 and 22. According to Sheil and Greenbaum (2005), in this same species, this occurs between stages 19 and 21, while in *M. temminckii* it occurs between stages 17 and 20 (SHEIL, 2005), and in *A. spinifera* between stages 17 and 22 (SHEIL, 2003). In *P. expansa*, with an intermediate period of duration, ossification of the maxillary arch occurred between stages 16 and 19.

The sequence of ossification, according to Rieppel (1993), is: squamosal > maxilla =

premaxilla > jugal > quadratojugal. This pattern suggests a tendency for rostrocaudal ossification of these elements. The sequence in *M. temimckii* (SHEIL, 2005) is: maxilla > premaxilla = jugal = squamosal > quadratojugal. In *A. spinifera* (SHEIL, 2003) the sequence is: maxilla = squamosal > jugal > quadratojugal > premaxilla, while in *P. expansa* the sequence is: squamosal = maxilla = premaxilla = jugal > quadratojugal. Although these elements ossify more rapidly in *P. expansa*, the sequence of ossification observed is closer to that reported by Rieppel (1993). Thus, it is evident that more quantitative studies are needed to document the natural variability of bone formation.

In both the studies on *C. serpentina*, bone elements that form the roof of the cranium are well ossified at the end of stage 21. The sequence of ossification, according to Rieppel (1993), is: postorbital > parietal > prefrontal = frontal, while for Sheil and Greenbaum (2005) it is: prefrontal > frontal = postorbital > parietal. The patterns of ossification of the elements of the skull of *C. serpentina* proposed by Rieppel (1993) and by Sheil and Greenbaum (2005) are not identical in all the points observed, although they belong to the same species. Sheil (2003) reported that in *P. expansa* and *A. spinifera*, all these elements already present dye retention in stage 19 and the sequence of ossification is frontal = postorbital = parietal > prefrontal in the former and parietal > prefrontal > frontal = postorbital in the latter. In *M. temimckii* (SHEIL, 2005), all these elements present an ossification center in stage 20 and the sequence also differs from the previous species, i.e., postorbital > frontal = prefrontal > parietal.

The differences are clearly visible in the studies carried out so far. In this context, what stand out are the differences in the chronology and sequence of ossification among some of the bones that make up the skeleton of the skull of *P. expansa* and the compared species.

#### Splanchnocranium, mandible and hyoid apparatus

In the two studies of *C. serpentina*, the bone elements of the mandible begin to ossify at the end of stage 21 (SHEIL; GREENBAUM, 2005; RIEPPEL, 1993), but with respect to the other structural units, the two studies seem to point to a significant variation in the sequence of ossification of these elements. Rieppel (1993) identified the following sequence of ossification of these elements: dentary > coronoid = supra-angular. The ossification of these elements was followed by that of the quadrate in the subsequent stage.

Essentially, the two studies on *C. serpentina* (RIEPEL, 1993; SHEIL; GREENBAUM, 2005)

show no major differences between the sequence and relative synchronization of ossification of the mandible, and these data coincide with those reported for *M. temimckii* (SHEIL, 2005), as well as for *P. expansa*, indicating a general tendency for rostrocaudal ossification. The does not hold true for *A. spinifera* (SHEIL, 2003), in which the chronology and sequence of ossification of the mandible differ: dentary > supra-angular > coronoid.

The sequence of bone development during ontogeny varies greatly among these species. According to Sahoo et al. (1998), osteogenesis, and possibly up to a point, patterns, are influenced by environmental conditions. Size and age are both important parameters for the pattern of bone formation. Chelonians of the same age may be in different stages of development, and there are significant variations even among animals of the same size (GILBERT et al., 2001).

In *C. serpentina* (SHEIL; GREENBAUM, 2005), branchial horns I and II of the hyoid apparatus ossify following the sequence: branchial horn I in stage 20 and branchial horn II in stage 22. A different process occurs in *P. expansa*, where branchial horn II remains in cartilage form and only branchial horn I ossifies, an event that occurs in stage 17. In *C. serpentina*, ossification begins distally and proceeds proximally, while in *P. expansa* the ossification center emerges in the center of the bone.

#### Conclusion

The bones of the dermatocranium and the mandible are the first to begin the ossification process: squamosal, pterygoid, maxilla, dentary, coronoid, supra-angular and branchial horn I in stage 16, the frontal, jugal, postorbital, parietal, premaxilla and prefrontal in stage 17, and the palatine and quadratojugal in stage 19. This is followed by ossification of the bones of the neurocranium: basisphenoid and basioccipital in stage 19, supraoccipital in stage 20, exoccipital in stage 21, and prooptic in stage 24. The quadrate bone of the splanchnocranium is the last to ossify, in stage 23.

#### References

- BELL, B.; SPOTILA, J. R.; CONGDON, J. High incidence of deformity in aquatic turtles in the John Heinz National Wildlife Refuge. **Environmental Pollution**, v. 142, n. 3, p. 457-465, 2006.
- BRONNER-FRASER, M. Neural crest cell formation and migration in the developing embryo. **FASEB Journal**, v. 8, n. 10, p. 699-706, 1994.

- CLARK, K.; BENDER, G.; MURRAY, B. P.; PANFILIO, K.; COOK, S.; DAVIS, R.; MURNEN, K.; TUAN, R. S.; GILBERT, S. F. Evidence for the neural crest origin of turtle plastron bones. **Genesis**, v. 31, n. 3, p. 111-117, 2001.
- DANNI, T. M. S.; DARDENNE, M. A. R.; NASCIMENTO, S. M. Estudo morfológico do desenvolvimento embrionário da tartaruga-da-amazônia, *Podocnemis expansa*, pelomedusidae. **Brazilian Journal of Biology**, v. 50, n. 3, p. 619-625, 1990.
- DAVIS, D. D.; GORE, U. R. Clearing and staining skeleton of small vertebrates. **Field Museum of Natural History Bulletin**, v. 4, n. 4, p. 3-15, 1936.
- DINGERKUS, G.; UHLER, L. Differential staining of bone and cartilage in cleared and stained fish using alcian blue to stain cartilage and enzymes for clearing fish. **Stain Technology**, v. 52, n. 4, p. 229-232, 1977.
- GASPAR, A.; RANGEL FILHO, F. B. Utilização de carne de tartarugas da Amazônia (*Podocnemis expansa*), criadas em cativeiro, para consumo humano. **Higiene Alimentar**, v.15, n. 89, p.73-78, 2001.
- GILBERT, S. F.; LOREDO, G. A.; BRUKMAN, A.; BURKE, A. C. Morphogenesis of the turtle shell: the development of novel structure in tetrapod evolution. **Evolution Development**, v. 3, n. 2, p. 47-58, 2001.
- GRAY, C.; BOYDE, A.; JONES, S. J. Topographically induced bone formation in vitro: implications for bone implants and bone grafts. **Bone**, v. 18, n. 2, p. 115-123, 1996.
- HILDEBRAND, M.; GOSLOW, G. E. **Análise da estrutura dos vertebrados**. São Paulo: Atheneu, 2006.
- HIRANO, L. Q. L.; SANTOS, A. L. Q.; PEREIRA, P. C.; SILVA, J. M. M.; KAMINISHI, A. P. S.; FERREIRA, C. G. Anatomia vascular das artérias renais e gonadais de *Podocnemis unifilis* Schweigger, 1812 (Testudines, Pelomedusidae). **Acta Scientiarum. Biological Sciences**, v. 31, n. 2, p. 191-194, 2009.
- MADER, D. R.; BENNETT, R. A.; FUNK, R. S.; FITZGERALD, K. T.; VERA, R.; HERNANDEZ-DIVERS, S. J. Surgery. In: MADER, D. R. (Ed.). **Reptile medicine and surgery**. 2<sup>nd</sup> ed. Saint Louis: Saunders Elsevier, 2006. cap. 3, p. 98-123.
- NAH, H. D.; PACIFICI, M.; GERSTENFELD, L. C.; ADAMS, S. L.; KIRSCH, T. Transient chondrogenic phase in the intramembranous pathway during normal skeletal development. **Journal of Bone and Mineral Research**, v. 15, n. 3, p. 522-533, 2000.
- OLSEN, B. R.; REGINATO, A. M.; WANG, W. Bone development. **Annual Review of Cell and Developmental Biology**, v. 16, p. 191-220, 2000.
- RIEPPPEL, O. Studies on skeleton formation in reptiles: patterns of ossification in the skeleton of *Chelydra serpentina* (Reptilia, Testudines). **Journal of Zoology**, v. 231, n. 3, p. 487-509, 1993.
- SAHOO, G.; SAHOO, R. K.; MOHANTY-HEJMADI, P. Calcium metabolism in olive ridley turtle eggs during embryonic development. **Comparative Biochemistry and Physiology. Part A**, v. 121, n. 1, p. 91-97, 1998.
- SHEIL, C. A. Osteology and skeletal development of *Apalone spinifera* (Reptilia: Testudines: Trionychidae). **Journal of Morphology**, v. 256, n. 1, p. 42-78, 2003.
- SHEIL, C. A. Skeletal development of *Macrochelys temminckii* (Reptilia: Testudines: Chelydridae). **Journal of Morphology**, v. 263, n. 1, p. 71-106, 2005.
- SHEIL, C. A.; GREENBAUM, E. Reconsideration of skeletal development of *Chelydra serpentina* (Reptilia: Testudinata: Chelydridae): evidence for intraspecific variation. **Journal of Zoology**, v. 265, n. 3, p. 235-267, 2005.

Received on November 12, 2008.

Accepted on February 13, 2009.

License information: This is an open-access article distributed under the terms of the Creative Commons Attribution License, which permits unrestricted use, distribution, and reproduction in any medium, provided the original work is properly cited.